



A Rare Cause of Nasal Obstruction: Concha Bullosa of the Inferior Turbinate

Emrah Sapmaz¹, Hilal Irmak Sapmaz², Yüksel Toplu³, Ramazan Öçalan¹, Işıl Çakmak Karaer¹

¹State Hospital, Otorhinolaryngology Clinic, Malatya, Turkey

²İnönü University, Faculty of Medicine, Department of Anatomy, Malatya, Turkey

³İnönü University, Faculty of Medicine, Department of Otorhinolaryngology, Malatya, Turkey

Abstract

Concha bullosa of the inferior turbinate is an extremely rare anatomic malformation. Inferior concha bullosa is the structure with air sacs on the inferior turbinate body and may be associated with maxillary sinus. Inferior concha bullosa is generally asymptomatic and diagnosed incidentally by computed tomography. Its main clinical symptoms are nasal obstruction, headache, and postnasal drip. Several techniques have been suggested as treatment options. With this study, we intend to report the case of a 23 year old woman who has nasal obstruction, headache, and postnasal drip was diagnosed with inferior, middle and superior concha bullosa and we have performed laterization through radiofrequency ablation on inferior turbinate and partial resection on the middle turbinate.

Key Words: Inferior Concha Bullosa; Nasal Congestion; Computed Tomography.

Burun Tıkanıklığının Nadir Bir Sebebi: İnförör Konka Bülloza

Özet

Inferior konka bülloza oldukça nadir görülen bir anatomik varyasyondur. İnförör konka bülloza, inferior konkanın kemik lamelinin içerisinde hava keseciğinin olmasıdır ve bazen bu hava kesesi maksiller sinüsle de alakalı olabilir. Genellikle asemptomatiktir ve görüntüleme yöntemleriyle tesadüfen tespit edilirdir. Bazen burun tıkanıklığı, baş ağrısı ve geniz akıntısı gibi semptomlarla neden olabilir. Tedavisinde çeşitli teknikler tarif edilmiştir. Biz bu makalede 23 yaşında burun tıkanıklığı, baş ağrısı ve geniz akıntısı nedeniyle kliniğimize baş vuran ve üst orta ve alt konklarda konka bülloza tespit ettiğimiz, inferior konka büllozanın tedavisinde lateralizasyon ve radyofrekansla ablasyon yaptığımız aynı zamanda orta konka büllozaya parsiyel rezeksiyon uyguladığımız bir bayan vakayı sunduk.

Anahtar Kelimeler: Alt Konka Bülloza; Nazal Tıkanıklık; Bilgisayarlı Tomografi.

INTRODUCTION

Stretching from the lateral nasal wall extending into the nose, nasal turbinates are crucial structures. Inferior turbinate, ethmoid and maxillary turbinate develop through the 8th to 10th weeks of fetal life (1). Concha bullosa (CB) is the pneumatization of the middle turbinate, and less commonly, of the top turbinate (2). Inferior concha bullosa (ICB) is the structure with air sacs on the inferior turbinate body and may be associated with maxillary sinus. Although middle turbinate pneumatization is fairly common, the pneumatization of the inferior turbinate is rare (3). It can either be unilateral or bilaterally (3,4).

CASE REPORT

A 23 year old female patient with continuous headache in the last year and complaints of breathlessness was admitted to our clinic. The patient did not have any history of trauma. In the anterior rhinoscopy and endoscopic examination, we have observed inferior turbinate on the left with a minimal septal deviation along with hypertrophy in the middle turbinates. Upon learning that previous medical treatment she was given

did not help and observing no allergens in the skin prick test, the patient was asked for a paranasal sinus tomography scan. The coronal paranasal sinus tomography showed pneumatization in the left inferior, middle and upper turbinates (Figure 1 and 2). Since the pneumatization in the inferior turbinate was connected to the maxillary sinus, we have performed laterization through radiofrequency ablation on inferior turbinate and partial resection on the middle turbinate. The patient had no intraoperative and postoperative problems. After 3 postoperative months, there was a significant reduction in symptoms.

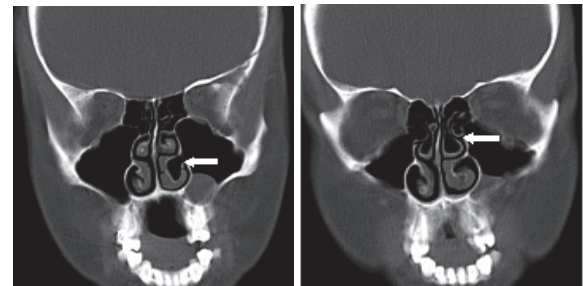


Figure 1. ICB (white arrow)

Figure 2. MCB ve UCB (white arrow)

DISCUSSION

Nasal turbinates are important structures in maintaining normal nasal functions. They are the most important substructures in moistening, directing and cleaning the air taken in through the nose (5). Generally, the lower turbinates become hypertrophied due to reasons such as allergic causes, being exposed to irritants, chronic sinus infections, and vasomotor rhinitis. In the presence of septal deviation, compensatory hypertrophy may occur in the turbinate as a response to the deviation. It is very rare for the hypertrophy of the inferior turbinate to stem from the pneumatized inferior turbinate. Unlike other turbinates, the embryological development of the inferior turbinates springs from what is called maxilloturbinal structures (6).

Among the major hypotheses concerning the formation of the pneumatized inferior turbinate, we can mention the double lamellar ossification of inferior concha between the 5th and 9th weeks followed by the invagination of the mucous membrane within the concha, and the extension of maxillary sinus aeration into the inferior turbinate. That the hypertrophy of the inferior turbinates causes nasal obstruction and that it is affected by surgical intervention have both clinical and surgical importance (7).

However, because the more important area is the middle meatus in endoscopic sinus surgery, middle turbinate variations attract more attention. This is the reason why variations of inferior turbinate are usually in the form of case reports. It was Zinreich et al. who evaluated ICB as a variation of the turbinates for first time in 1988 (8). Yang et al. (9) among 59,238 tomographic scans of the paranasal sinuses have identified ICB in a total of 16 patients, two of them being bilateral ICB. Similarly, Christmas et al. have reported three ICB cases that caused nasal blockage (10).

ICB is usually asymptomatic and is usually diagnosed by imaging methods (2, 11). If there is a wide range of ventilation, it can cause nasal congestion. In addition to congestion, it may also lead to nasal discharge, co-infections, headaches and epiphora (12, 13). Clinically, it may not be easy to differentiate it from hypertrophied turbinates. At this point, applying decongestant can be useful for the differential diagnosis.

ICB should be treated when it is symptomatic. Maximum air passages and mucosal functions should be maintained during the treatment. Nasal steroids may be administered as a medical treatment but often the problem does not respond well and surgical intervention may be required. Turbinoplasty with microdebrider, submucosal diathermy, radiofrequency ablation, resection of the free wall, breaking the wall with forceps are among the surgical techniques offered for the treatment (2,14).

Due to the fact that it has been tried many times with positive results, the resection of the lateral wall is

commonly used but in cases in which ventilation is connected to the maxillary sinus, this method is contraindicated (4).

It has been suggested that applying the resection to such patients may lead to iatrogenic sub-meatal antrostomy. It has been argued that, in these cases, the resection may disrupt the physiology of the maxillary sinus and initiate mucous recirculation phenomena (2). In cases with small pneumatization, it may even be enough to break the lateral wall by just pushing it towards medial (15). Because it may result in atrophic rhinitis, the removal of the whole inferior turbinate or damaging the mucosa is contraindicated (16).

As a result of the relationship between the inferior turbinate and the maxillary sinus as observed in the computerized tomography, and the insufficient improvement in the turbinate hypertrophy after the administration of mucosal decongestants and steroids, we preferred radiofrequency ablation and lateralization in our patient's case.

Consequently, ICB should be considered in the differential diagnosis of patients with nasal obstruction and hypertrophied inferior turbinate.

REFERENCES

1. Bolger WE, Butzin CA, Parsons DS. Paranasal sinus bony anatomic variations and mucosal abnormalities: CT analysis for endoscopic sinus surgery. *Laryngoscope* 1991;101:56-64.
2. Unlu HH, Altuntas A, Aslan A, Eskiizmir G, Yucel A. Inferior concha bullosa. *J Otolaryngol* 2002;31:62-4.
3. Dawlaty EE. Inferior concha bullosa--a radiological and clinical rarity. *Rhinology* 1999;37:133-5.
4. Dogru H, Doner F, Uygur K, Gedikli O, Cetin M. Pneumatized inferior turbinate. *Am J Otolaryngol* 1999;20:139-41.
5. Pittore B, Al Safi W, Jarvis SJ. Concha bullosa of the inferior turbinate: an unusual cause of nasal obstruction. *Acta Otorhinolaryngol Ital*;31:47-9.
6. Braun H, Stammberger H. Pneumatization of turbinates. *Laryngoscope* 2003;113:668-72.
7. Spear SA, Brietzke SE, Winslow C. Bilateral bifid inferior turbinates. *Ann Otol Rhinol Laryngol* 2003;112:195-6.
8. Zinreich SJ, Mattox DE, Kennedy DW, Chisholm HL, Diffley DM, Rosenbaum AE. Concha bullosa: CT evaluation. *J Comput Assist Tomogr* 1988;12:778-84.
9. Yang BT, Chong VF, Wang ZC, Xian JF, Chen QH. CT appearance of pneumatized inferior turbinate. *Clin Radiol* 2008;63:901-5.
10. Christmas DA, Jr., Merrell RA, Jr., Mirante JP, Yanagisawa E. Pneumatized inferior turbinate: report of three cases. *Ear Nose Throat J* 2004;83:152-3.
11. Aydin O, Ustundag E, Ciftci E, Keskin IG. Pneumatization of the inferior turbinate. *Auris Nasus Larynx* 2001;28:361-3.
12. Kiroglu AF, Cankaya H, Yuca K, Kara T, Kiris M. Isolated turbinitis and pneumatization of the concha inferior in a child. *Am J Otolaryngol* 2007;28:67-8.
13. Gocmen H, Oguz H, Ceylan K, Samim E. Infected inferior turbinate pneumatization. *Eur Arch Otorhinolaryngol* 2005;262:979-81.
14. Ozcan KM, Gedikli Y, Ozcan I, Pasaoglu L, Dere H. Microdebrider for reduction of inferior turbinate: evaluation of effectiveness by computed tomography. *J Otolaryngol Head Neck Surg* 2008;37:463-8.

15. Cannon CR. Endoscopic management of concha bullosa. Otolaryngol Head Neck Surg 1994;110:449-54.

16. Clement WA, White PS. Trends in turbinate surgery literature: a 35-year review. Clin Otolaryngol Allied Sci 2001;26:124-8.

Received/Başvuru: 29.08.2013, Accepted/Kabul: 04.10.2013

Correspondence/İletişim

Emrah SAPMAZ
State Hospital, Otorhinolaryngology Clinic, MALATYA,
TURKEY
E-mail: emrhils@yahoo.com



For citing/Atıf için

Sapmaz E, Irmak Sapmaz H, Toplu Y, Ocalan R, Cakmak Karaer I. A rare cause of nasal stuffiness: Inferior concha bullosa. J Turgut Ozal Med Cent 2014;21:145-7 DOI: 10.7247/jtomc.2013.1221