

Etomidate alleviates ovarian ischemia-reperfusion injury in rats

¹ Vildan Kölükçü,¹ ² Mehtap Gürlür Balta,¹ ³ Hakan Tapar,¹ ⁴ Tuğba Karaman,¹ ⁵ Serkan Karaman,¹
⁶ Velid Unsal,² ⁷ Fikret Gevrek,³ ⁸ Muzaffer Katar⁴

¹Department of Anesthesiology and Reanimation, Tokat Gaziosmanpaşa University Faculty of Medicine, Tokat-Türkiye

²Mardin Artuklu University, Faculty of Health Sciences and Central Research Laboratory, Mardin-Türkiye

³Department of Histology And Embryology, Tokat Gaziosmanpaşa University Faculty of Medicine, Tokat-Türkiye

⁴Department of Biochemistry, Tokat Gaziosmanpaşa University Faculty of Medicine, Tokat-Türkiye

ABSTRACT

BACKGROUND: This study investigates the protective effects of etomidate against oxidative damage in an experimental model of ovarian ischemia-reperfusion injury.

METHODS: A total of 24 female rats were randomized into three groups. Group 1 served as the control. Group 2 underwent an ovarian torsion/detorsion procedure. Group 3 underwent similar procedures as Group 2; additionally, 4 mg/kg of etomidate was administered intraperitoneally 30 minutes before ovarian detorsion. Blood samples were analyzed for lipid peroxidation, pro-inflammatory cytokine levels, and antioxidant enzyme activity. Furthermore, histopathological scoring was performed to evaluate tissue damage in the ovaries.

RESULTS: Biochemical analysis of blood samples revealed reductions in pro-inflammatory cytokines, including interleukin-1 Beta (IL-1 β), interleukin-6 (IL-6), and tumor necrosis factor-alpha (TNF- α), in Group 3 compared to Group 2 ($p=0.005$, $p=0.016$, and $p<0.001$, respectively). Additionally, a decrease in malondialdehyde (MDA) levels was observed in Group 3 compared to Group 2 ($p<0.001$). In contrast, activities of antioxidant enzymes, including superoxide dismutase (SOD) and glutathione peroxidase (GSH-PX), were significantly increased in Group 3 compared to Group 2 ($p=0.031$ and $p=0.001$, respectively). Furthermore, Group 3 demonstrated notable reductions in histopathological scores for follicular degeneration, vascular occlusion, bleeding, and inflammation compared to Group 2 ($p<0.001$, $p<0.001$, $p<0.001$, and $p=0.001$, respectively).

CONCLUSION: Etomidate alleviates ischemia-reperfusion injury in a rat ovarian torsion-detorsion model by improving both histopathological and biochemical outcomes.

Keywords: Etomidate; ovarian torsion and detorsion; ischemia-reperfusion injury; oxidative stress.

INTRODUCTION

Ovarian torsion is a critical gynecological emergency characterized by the rotation of the adnexa around its axis and vascular pedicle. This condition predominantly affects women of reproductive age, though it can occur at any age. The incidence of ovarian torsion varies, with rates reported from 2.5%

to 7.4%.^[1,2] Major risk factors include ovarian cysts, pelvic surgeries, ovarian hyperstimulation syndrome, trauma, previous episodes of ovarian torsion, polycystic ovary syndrome, and pregnancy.^[1,3] Patients commonly present to the emergency department with clinical symptoms like lower abdominal pain, nausea, vomiting, and fever. However, specific laboratory markers are notably absent.^[3] Color Doppler sonography is

Cite this article as: Kölükçü V, Gürlür Balta M, Tapar H, Karaman T, Karaman S, Unsal V, Gevrek F, Katar M. Etomidate alleviates ovarian ischemia-reperfusion injury in rats. *Ulus Travma Acil Cerrahi Derg* 2024;30:375-381.

Address for correspondence: Vildan Kölükçü

Tokat Gaziosmanpaşa University Faculty of Medicine, Tokat, Türkiye

E-mail: vildankolukcu@gmail.com

Ulus Travma Acil Cerrahi Derg 2024;30(6):375-381 DOI: 10.14744/tjtes.2024.27388

Submitted: 23.11.2023 Revised: 05.01.2024 Accepted: 30.04.2024 Published: 11.06.2024

OPEN ACCESS This is an open access article under the CC BY-NC license (<http://creativecommons.org/licenses/by-nc/4.0/>).



commonly employed as an auxiliary diagnostic tool.^[4] Prompt and accurate diagnosis, followed by early surgical intervention, is crucial to preserve ovarian tissue.^[1,5] Delays in diagnosing and treating ovarian torsion may lead to loss of the ovary or a serious decrease in follicle reserve.^[6] For this reason, performing detorsion procedures is critical to maintain the viability of ischemic ovarian tissue.^[7] However, these procedures can also induce adverse changes in the tissue. Reoxygenation of hypoxic tissue leads to the formation of excessive reactive oxygen species (ROS).^[8] When ROS levels exceed the tissue's antioxidant capacity, it results in inflammation and severe oxidative damage.^[3] This sudden surge in oxidative stress can cause lipid oxidation, dysfunction in protein metabolism, disruption of the cytoskeletal structure, and damage to the genomic sequence.^[1,3] Consequently, the restoration of blood flow paradoxically causes ischemia-reperfusion damage in the ovarian tissue. Over recent years, extensive research has been conducted on numerous pharmacological agents with antioxidant and anti-inflammatory properties to minimize the harmful effects of ovarian ischemia-reperfusion injury.^[7]

Etomidate, known chemically as R-1-(1-ethylphenyl)imidazole-5-ethyl ester, is an ultra-short-acting, non-barbiturate hypnotic agent used for the induction of general anesthesia and sedation.^[9-11] Etomidate is a highly selective agonist for gamma-aminobutyric acid type A receptors. Owing to its stable hemodynamic profile and the fact that it does not induce cardiovascular or respiratory depression, etomidate is the preferred anesthetic for facilitating tracheal intubation in operating rooms, intensive care units, and emergency departments.^[10,12] In addition to its reliably high therapeutic index, recent pharmaceutical research has uncovered that etomidate possesses antioxidant and anti-inflammatory properties. Consequently, studies in recent years have demonstrated etomidate's protective effects against ischemia-reperfusion injury in various organs.^[13]

However, the use of etomidate in the female reproductive system is quite limited. This study aims, for the first time in the English literature, to examine the potential protective effects of etomidate against ischemia-reperfusion injury following treatment for ovarian torsion.

MATERIALS AND METHODS

Experimental Animals and Laboratory Environment Ethical approval was obtained from our university's local ethics committee (2023 HADYEK-06) for all surgical and experimental procedures. We utilized 24 female Albino-Wistar rats, weighing between 270 and 450 grams, for this study. The experiment was conducted under a 12-hour light/dark cycle at a constant temperature of $22 \pm 2^\circ\text{C}$ and a humidity level of $50 \pm 5\%$. Experimental animals were cared for in accordance with the National Research Council's Guide for the Care and Use of Laboratory Animals, as well as institutional guidelines.

Formation of Experimental Groups and Surgical Procedures

All surgical procedures were conducted under sterile condi-

tions in appropriate laboratory environments using xylazine/ketamine anesthesia.

• Group 1: Control Group

This group comprised rats that underwent a laparotomy via a midline abdominal incision. No further manipulations were made. Blood samples were collected from the rats in this group for basal biochemical analyses, and bilateral oophorectomies were performed for histopathological evaluations.^[4]

• Group 2: Ovarian Ischemia-Reperfusion Group

Rats in this group underwent an ovarian torsion/detorsion procedure as previously described in the literature. A 2 cm vertical midline incision was made. The ovaries, fallopian tubes, and ovarian blood vessels were rotated 360 degrees clockwise, and secured to the abdominal wall using 5/0 silk for three hours. After torsion was released, reperfusion was allowed for another three hours. Subsequently to this, blood samples were taken for biochemical analyses, and bilateral oophorectomies were carried out for histopathological evaluations.^[4]

• Group 3: Treatment Group

A similar ovarian torsion/detorsion procedure to Group 2 was applied, with the addition of 4 mg/kg of etomidate administered intraperitoneally 30 minutes prior to reperfusion.^[14] Blood samples were then collected for biochemical analyses, and bilateral oophorectomies were conducted for histopathological evaluations.

Histopathological Examination

The ovarian tissues were fixed in 4% buffered neutral formalin solution for 72 hours. Consecutive thin serial sections of 5 μm thickness were obtained from the embedded ovaries using a Leica RM2135 rotary microtome (Germany). The sections were placed on frosted slides with ground edges for hematoxylin and eosin staining and prepared for histopathological analyses to assess tissue damage. Ovarian tissue sections stained with hematoxylin and eosin from the study groups were examined under a Nikon Eclipse 200 light microscope (Japan), utilizing a 40x objective. Microscopic examinations were conducted on each sample using a systematic root work approach, analyzing an average of 5-6 consecutive sections per sample. Within each section, five different areas were randomly selected for evaluation, employing a blind coding system that concealed group information. A senior histologist analyzed the specimens, using an ovarian tissue damage scoring system where damage was graded on a scale from 0 to 3 (0 = none, 1 = mild, 2 = moderate, 3 = severe), based on criteria including follicle cell degeneration, vascular congestion, hemorrhage, and inflammation.^[15]

Biochemical Analyses

Blood samples collected for biochemical analysis were centrifuged at 4°C and 4000 rpm for 10 minutes after being placed in tubes. The serum obtained from these samples was then frozen and stored at -20°C . Chemical materials of both com-

Table 1. Comparison of SOD and GSH-Px activities, and levels of TNF- α , IL-1 β , IL-6, and MDA in blood samples among rat groups

	Group	n	Mean \pm SD	Min-Max	p-Values	Post Hoc p-Values
SOD (U/mL)	1	8	9.25 \pm 1.88	5.44-11.2	<0.001*	1-2<0.001*
	2	8	5.6 \pm 0.88	4.76-7.21		1-3:0.046*
	3	8	7.49 \pm 1.17	5.43-8.87		2-3:0.031*
GSH-Px (U/mL)	1	8	447.66 \pm 57.83	351-521	<0.001*	1-2<0.001*
	2	8	248.03 \pm 45.67	200.1-334.1		1-3:0.025*
	3	8	367.13 \pm 64.21	265.1-445.2		2-3:0.001*
MDA (μ mol/mL)	1	8	7.31 \pm 1.72	5.21-10.2	<0.001*	1-2<0.001*
	2	8	12.08 \pm 0.87	11.2-13.1		1-3:0.048*
	3	8	9.24 \pm 0.74	8.23-10.03		2-3<0.001*
TNF- α (ng/L)	1	8	324.88 \pm 64.94	232.1-441.2	<0.001*	1-2<0.001*
	2	8	586.9 \pm 44.57	521.3-622.1		1-3:0.549
	3	8	381.01 \pm 40.88	307.1-441.2		2-3<0.001*
IL-1 β (ng/mL)	1	8	14.86 \pm 4.27	10.87-20.7	<0.001*	1-2<0.001*
	2	8	30.73 \pm 5.78	21.98-41.2		1-3:0.509
	3	8	21.2 \pm 6.01	11.7-28.1		2-3:0.005*
IL-6 (ng/L)	1	8	12.89 \pm 1.77	10.98-15.4	<0.001*	1-2<0.001*
	2	8	25.54 \pm 5.28	15.76-29.45		1-3:0.701
	3	8	17.1 \pm 4.94	11.2-24.4		2-3:0.016*

Abbreviations: GSH-Px: Glutathione Peroxidase; IL-1 β : Interleukin 1 Beta; IL-6: Interleukin 6; MDA: Malondialdehyde; SD: Standard Deviation; SOD: Superoxide Dismutase; TNF- α : Tumor Necrosis Factor Alpha. Test used: One-Way Analysis of Variance (ANOVA), (Differences between groups were examined using either Post Hoc Tukey's HSD or Tamhane's T2), *Statistically significant difference ($p<0.05$).

mercial and analytical grade were supplied by Sigma-Aldrich, Merck, Alfa Aesar, Acros Organics B.V.B.A., Tekkim, and Iso-lab for the examination of various parameters. The following parameters were analyzed:

• **Superoxide Dismutase (SOD) Activity:** Assessed by the inhibition of nitroblue tetrazolium reduction via the xanthine-xanthine oxidase system, serving as a superoxide radical generator.^[16]

• **Glutathione Peroxidase (GSH-Px) Activity:** Measured through an enzymatic reaction initiated by adding H₂O₂ to the reaction mixture containing reduced glutathione, nicotinamide adenine dinucleotide phosphate, and glutathione reductase.^[17]

• **Malondialdehyde (MDA) Levels:** Determined through a reaction with thiobarbituric acid at temperatures ranging from 90-100°C.^[18]

• Interleukin-1 Beta (IL-1 β), Interleukin-6 (IL-6), and Tumor Necrosis Factor-Alpha (TNF- α) were quantified using enzyme-linked immunosorbent assay (ELISA) kits as per the instructions provided in the accompanying prospectuses.

Statistical Analysis

Descriptive statistics provided insights into the general characteristics of the study groups. Variables were described using means \pm standard deviations and ranges (min-max). Differences between groups were assessed using one-way analysis of variance (ANOVA). Post-hoc comparisons were made using Tukey's Honestly Significant Difference (HSD) or Tamhane's T2 tests as appropriate. Ready-to-use statistical software was used for the calculations (IBM SPSS Statistics

22, SPSS Inc., and IBM Co., Somers, NY).

RESULTS

Biomechanical Findings

Our biochemical analysis results are summarized in Table 1. The level of MDA, an end product of lipid peroxidation, was measured at 12.08 \pm 0.87 in Group 2, significantly higher than in Group 1 ($p<0.001$). In Group 3, the MDA level decreased to 9.24 \pm 0.74, significantly lower than in Group 2 ($p<0.001$). The levels of proinflammatory cytokines in Group 3—IL-1 β , IL-6, and TNF- α —were recorded as 21.2 \pm 6.01, 17.1 \pm 4.94, and 381.01 \pm 40.88, respectively, showing significant suppression compared to Group 2 ($p=0.005$, $p=0.016$, and $p<0.001$, respectively). Antioxidant enzyme activities, specifically SOD and GSH-Px, were significantly higher in Group 3 compared to Group 2 ($p=0.031$ and $p=0.001$, respectively).

Histopathological Findings

Detailed comparisons of ovarian damage histopathological scores across the groups are presented in Table 2. The levels of follicular cell degeneration, vascular congestion, and hemorrhage in Group 2 were significantly increased compared to Group 1 ($p<0.001$). Conversely, in Group 3, the scores for follicular cell degeneration, vascular congestion, and hemorrhage were 1.04 \pm 0.32, 1.15 \pm 0.37, and 1.23 \pm 0.18, respectively. These values were lower than those in Group 2 ($p<0.001$). Similarly, the inflammation score was recorded as 2.14 \pm 0.4 in Group 2, which was significantly higher than in the other groups ($p<0.001$). In Group 3, the inflammation score was markedly reduced ($p=0.001$). Additionally, the total ovarian

Table 2. Comparison of histopathological scores for ovarian damage among groups

	Group	n	Mean±SD	Min-Max	p-Values	Post Hoc p-Values
Follicular Cell Degeneration	1	8	0.15±0.04	0.08-0.21	<0.001*	1-2<0.001*
	2	8	2.19±0.37	1.65-2.63		1-3:0.001*
	3	8	1.04±0.32	0.45-1.39		2-3<0.001*
Vascular Congestion	1	8	0.18±0.08	0.07-0.29	<0.001*	1-2<0.001*
	2	8	2.22±0.34	1.83-2.67		1-3:0.001*
	3	8	1.15±0.37	0.42-1.62		2-3<0.001*
Hemorrhage	1	8	0.1±0.04	0.05-0.14	<0.001*	1-2<0.001*
	2	8	2.3±0.31	1.96-2.7		1-3<0.001*
	3	8	1.23±0.18	0.93-1.45		2-3<0.001*
Inflammatory Cell Infiltration	1	8	0.12±0.05	0.04-0.19	<0.001*	1-2<0.001*
	2	8	2.14±0.4	1.64-2.67		1-3<0.001*
	3	8	1.14±0.25	0.78-1.39		2-3:0.001*
Total Ovarian Damage Score	1	8	0.14±0.06	0.40-0.29	<0.001*	1-2<0.001*
	2	8	2.21±0.34	1.64-2.70		1-3<0.001*
	3	8	1.14±0.28	0.42-1.62		2-3<0.001*

Test used: One-Way Analysis of Variance (ANOVA), (Differences between groups were examined using either Post Hoc Tukey's HSD or Tamhane's T2).

*Statistically significant difference (p<0.05).

damage score was significantly improved in Group 3 compared to Group 2, recording a value of 1.14 (p<0.001).

DISCUSSION

Ovarian torsion ranks as the fifth most common gynecological emergency.^[3] The primary pathophysiology of ovarian torsion involves the rotation of the ovary around the infundibulopelvic ligament. This rotation of the ligament around itself leads to the blockage of arterial, venous, and lymphatic flow. The resulting venous and lymphatic blockage leads to edema in the ovarian tissue, followed by ischemia, which can progress to ovarian necrosis due to the significant reduction in arterial blood flow.^[5,19] Ischemia is defined as cell death resulting from inadequate tissue perfusion, depletion of cellular energy reserves, and the accumulation of toxic metabolites. The restoration of blood flow is crucial for the survival of cells.^[1,20] However, the reperfusion of ischemic tissue, accompanied by an increase in ROS, paradoxically causes ischemia-reperfusion injury, which is significantly more detrimental to the tissue than ischemia alone.^[1,20]

In ovarian torsion, an increase in lactic acid and hypoxanthine occurs as a secondary effect of reduced tissue oxygenation. Following the ovarian detorsion and subsequent reoxygenation, hypoxanthine is converted to uric acid by xanthine oxidase, resulting in a significant production of ROS due to the reintroduction of oxygen.^[8] The toxic effects of ROS, such as superoxide anion, hydrogen peroxide, and hydroxyl radicals, cause the oxidation of unsaturated fatty acids in the cell membrane, leading to lipid peroxidation.^[4] This cascade

of reactions leads to the synthesis and release of MDA,^[2] making MDA a valuable indicator of ischemia-reperfusion injury due to the high susceptibility of cell membrane lipids to free radical damage, which can lead to cell death.^[4] Significant increases in MDA levels have been consistently observed in numerous ovarian ischemia-reperfusion studies on rat models performed in the past.^[2,21] Similarly, our study confirmed a significant elevation in MDA levels in rats subjected to ischemia-reperfusion injury. The body has robust endogenous antioxidant systems that protect against tissue damage. Key components of this antioxidant system include GSH-Px and SOD. GSH helps maintain the -SH groups in proteins in a reduced state, thus preventing their oxidation. Meanwhile, SOD catalyzes the conversion of superoxide free radicals into hydrogen peroxide and molecular oxygen. These two enzymes shield tissues from the harmful effects of free radicals. Previous experimental studies have shown that GSH and SOD are significantly reduced following ovarian ischemia-reperfusion injury.^[7,20] Similarly, in our study, we observed a decrease in SOD and GSH activities in rats subjected to ischemia-reperfusion injury. Additionally, ROS, abundant in the environment, triggers inflammation.^[3] After reperfusion, leukocytes are activated. These inflammatory cells lead to the activation of nuclear transcription factors and the synthesis of pro-inflammatory cytokines such as TNF- α and interleukin-1 beta. ROS and leukocytes initiate the inflammatory process, leading to microvascular occlusion and contributing to cell damage.^[22] Recent experimental studies have shown that inflammatory markers related to ovarian ischemia-reperfusion injury are elevated in blood analyses, and direct microscopic

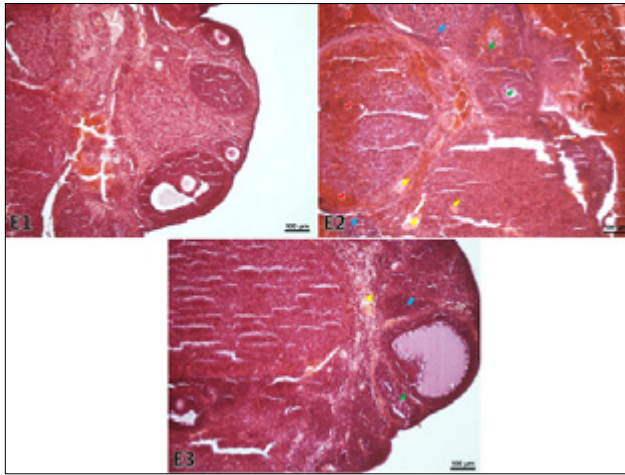


Figure 1. Microscopic images of ovarian tissue from different groups. Control Group (E1): Displays normal ovarian tissue. Ischemia-Reperfusion Group (E2): Shows disrupted overall tissue structure, including parenchymal and stromal tissue damage. Notable features include follicular cell degeneration (green arrow), inflammation (blue arrow), vascular congestion (yellow arrow), and extensive hemorrhagic areas (red arrow). Treatment Group (E3): Demonstrates significant reduction in tissue damage. Staining: Hematoxylin and Eosin; Scale bar: 100 µm.

examination has revealed significant increases in leukocyte infiltration in tissues.^[1,7] Similarly, in our study, there was an observed increase in IL-1 β , IL-6, and TNF- α levels, and histopathological examinations revealed a significantly high inflammation score in the rat group subjected to ischemia-reperfusion injury.

Etomidate, an imidazole derivative initially developed as an antifungal agent, has been found to exhibit hypnotic activity in animal studies. In 1972, it was introduced into routine medical practice as the first non-barbiturate intravenous anesthetic.^[9,10] The onset of action for etomidate occurs in less than one minute,^[10,23] and it is 75% protein bound. It is metabolized into an inactive carboxylic acid metabolite, with an elimination half-life of 2.9 to 5.5 hours.^[10] Etomidate does not inhibit sympathetic tone and myocardial function, and allergic reactions secondary to its use are very rare, as it does not cause histamine release. Additionally, it does not cause significant respiratory depression.^[9,10] Due to its favorable hemodynamic profile, etomidate offers considerable advantages for anesthesiologists during the induction of general anesthesia in patients with cardiac defects undergoing cardiac surgery. It is also favored by many emergency physicians for rapid induction and intubation in cases of hemorrhagic shock, thanks to these properties.^[9] Moreover, etomidate has been shown to significantly reduce cerebral blood flow and increase vascular resistance across all cerebral vessels. This pharmacological agent is reported to be beneficial in cases requiring intubation due to head trauma or cerebrovascular attacks, providing substantial support to healthcare professionals.^[23]

Beyond these benefits, detailed studies have demonstrated that etomidate ameliorates ischemia-reperfusion injury. Its

mechanism of action primarily involves the inhibition of oxidative stress, apoptosis, and inflammation.^[23] A clinical study by Li et al. analyzed patients who underwent surgery for tibia fractures and found that etomidate effectively maintained serum SOD activity and reduced secondary inflammation associated with ischemia-reperfusion injury of the fracture, leading to lower complication rates.^[24] Similarly, Yin et al. demonstrated that etomidate minimizes oxidative stress induced by IL-1 β in chondrocytes by decreasing ROS levels and increasing GSH-Px activity.^[13] Zhao et al. observed that etomidate protected retinal ganglion cells by activating the antioxidative stress response in rats with optic nerve transection.^[25] In an experimental study, Xie et al. reported that etomidate improved myocardial ischemia-reperfusion injury by inhibiting oxidative stress, fibrosis, and inflammation.^[26] Similarly, Jia et al. observed that in models of hyperoxia-induced acute lung injury in rats, etomidate suppressed the activation of pro-inflammatory factors, inhibited lipid peroxidation, and activated antioxidant enzymes. This effectively reduced morphological damage, such as pulmonary edema and inflammatory infiltration in the lung tissue.^[27] In another study by Yu et al., etomidate demonstrated neuroprotective activity by activating endogenous antioxidant systems and preserving ion balance in spinal cord ischemia-reperfusion injury.^[28] Similarly, our study found that etomidate improved follicular cell degeneration, vascular congestion, and hemorrhage scores by increasing SOD and GSH-Px levels. Demirkapu et al. histopathologically documented that in a rat model of testicular ischemia-reperfusion injury, etomidate reduced oxidative damage, inflammation, and ROS levels in the ipsilateral testis, thereby mitigating germ cell damage and preventing Leydig cell loss.^[14] Additionally, our research has documented that etomidate exhibits anti-inflammatory properties by suppressing elevated levels of IL-1 β , IL-6, and TNF- α that increase secondary to ischemia-reperfusion injury, and it minimizes lipid peroxidation.

Etomidate is considered one of the essential pharmacological agents for anesthesiologists managing critical patients due to its reliable sedative effectiveness and stable hemodynamic effects.^[27] As demonstrated in this study, etomidate has a healing effect on ischemia-reperfusion injury. However, some adverse effects associated with etomidate have been reported, including local pain, myoclonic movements, postoperative nausea, vomiting, and adrenal cortical inhibition.^[9]

Limitations of This Study

Due to technical constraints, our study could not analyze the adverse effects of etomidate in rats. Other limitations include the inability to perform immunohistochemical analyses, reliance solely on tissue biochemical analyses, and a focus only on the early outcomes of etomidate treatment.

CONCLUSION

Our study is the first in the English literature to evaluate the effectiveness of etomidate in a rat model of ovarian torsion-

detorsion. According to our findings, etomidate proved to be a highly effective pharmacological agent in suppressing inflammation secondary to ovarian ischemia/reperfusion injury, reducing oxidative damage, and protecting ovarian tissue. For our study to provide guidance for routine medical practices, future large-scale randomized studies are necessary.

Ethics Committee Approval: This study was approved by the Tokat Gaziosmanpaşa University Ethics Committee (Date: 11.05.2023, Decision No: 51879863-26).

Peer-review: Externally peer-reviewed.

Authorship Contributions: Concept: V.K., S.K., M.G.B., T.K., U.U., H.T.; Design: V.K., M.G.B., H.T., T.K., U.U.; Supervision: U.K., U.U., F.G., M.G.B., M.K., T.K.; Resource: U.K., S.K., U.U., T.K., M.G.B.; Materials: U.K., F.G., U.U., M.K.; Data collection and/or processing: V.K., F.G., U.U., M.K.; Analysis and/or interpretation: U.U., M.G.B., M.K., H.T., U.U., F.G.; Literature search: V.K., S.K., M.G.B., T.H., H.T.; Writing: A.V.K., S.K., T.K., H.T.; Critical reviews: V.K., S.K., M.G.B., T.K., H.T.

Conflict of Interest: None declared.

Use of AI for Writing Assistance: Not declared.

Financial Disclosure: The author declared that this study has received no financial support.

REFERENCES

- Topcu A, Balik G, Atak M, Mercantepe T, Uydu HA, Tumkaya L. An investigation of the effects of metformin on ovarian ischemia-reperfusion injury in rats. *Eur J Pharmacol* 2019;865:172790.
- Colak S, Gurlek B, Topcu A, Tumkaya L, Mercantepe T, Yilmaz A. Protective effects of nebulolol on ovarian ischemia-reperfusion injury in rat. *J Obstet Gynaecol Res* 2020;46:2407–16.
- Kaplan S, Türk A. Effects of vitamin B12 on rat ovary with ischemia-reperfusion injury. *Biotech Histochem* 2022;97:284–9.
- Gezer Ş, Başaran M. The protective effect of letrozole in a rat ovarian ischemia-reperfusion injury model. *Van Tıp Derg* 2020;27:407–14.
- Ozler A, Turgut A, Soydiñ HE, Sak ME, Evsen MS, Alabalik U, et al. The biochemical and histologic effects of adnexal torsion and early surgical intervention to unwind detorsion on ovarian reserve: an experimental study. *Reprod Sci* 2013;20:1349–55.
- Kavak SB, Kavak E, Kurkut B, İlhan R, Başpınar M. The importance of clinical, radiologic and laboratory parameters in the diagnosis of ovarian torsion: retrospective study. *İKSST Derg* 2014;6:20–2.
- Kavak EC, Bulmus FG, Bulmus O, Kavak SB, Kocaman N. Magnesium: does it reduce ischemia/reperfusion injury in an adnexal torsion rat model? *Drug Des Devel Ther* 2018;12:409–15.
- Cigremis Y, Kart A, Karaman M, Erdag D. Attenuation of ischemia-reperfusion injury with Marrubium cordatum treatment in ovarian torsion-detorsion model in rabbits. *Fertil Steril* 2010;93:1455–63.
- Forman SA. Clinical and molecular pharmacology of etomidate. *Anesthesiology* 2011;114:695–707.
- Valk BI, Struys MMRF. Etomidate and its analogs: a review of pharmacokinetics and pharmacodynamics. *Clin Pharmacokinet* 2021;60:1253–69.
- Jia L, Hao H, Wang C, Wei J. Etomidate attenuates hyperoxia-induced acute lung injury in mice by modulating the Nrf2/HO-1 signaling pathway. *Exp Ther Med* 2021; 22: 785.
- Wagner CE, Bick JS, Johnson D, Ahmad R, Han X, Ehrenfeld JM, et al. Etomidate use and postoperative outcomes among cardiac surgery patients. *Anesthesiology* 2014;120:579–89.
- Yin M, Xu Y. The protective effects of etomidate against interleukin-1 β (IL-1 β)-induced oxidative stress, extracellular matrix alteration and cellular senescence in chondrocytes. *Bioengineered* 2022;13:985–94.
- Demirkapı MJ, Karabag S, Akgul HM, Mordeniz C, Yananlı HR. The effects of etomidate on testicular ischemia reperfusion injury in ipsilateral and contralateral testes of rats. *Eur Rev Med Pharmacol Sci* 2022;26:211–7.
- Kalyoncu Ş, Yılmaz B, Demir M, Tuncer M, Bozdağ Z, Ince O, et al. Melatonin attenuates ovarian ischemia reperfusion injury in rats by decreasing oxidative stress index and peroxynitrite. *Turk J Med Sci* 2020;50:1513–22.
- Sun Y, Oberley LW, Li Y. A simple method for clinical assay of superoxide dismutase. *Clin Chem* 1988;34:497–500.
- Paglia DE, Valentine WN. Studies on the quantitative and qualitative characterisation of erythrocyte glutathione peroxidase. *J Lab Clin Med* 1967;70:158–69.
- Esterbauer H, Cheeseman KH. Determination of aldehydic lipid peroxidation products: malonaldehyde and 4-hydroxynonenal. *Methods Enzymol* 1990;186:407–21.
- Boynukalın FK, Güven S, Güven ES, Polat M. Overview of ovarian torsion. *Kocatepe Med J* 2016;17:30–5.
- Incec M, Isaoglu U, Yilmaz M, Calik M, Polat B, Alp HH, et al. Prevention of ischemia-reperfusion injury in rat ovarian tissue with the on-off method. *J Physiol Pharmacol* 2011;62:575–82.
- Karaçor T, Dogan Z, Elibol E, Bulbul M, Nacar MC. Effects of iloprost on experimental ischemia and reperfusion injury in rat ovary. *Biotech Histochem* 2020;95:373–80.
- Çaltekin MD, Özkut MM, Çaltekin İ, Kaymak E, Çakır M, Kara M, et al. The protective effect of JZL184 on ovarian ischemia reperfusion injury and ovarian reserve in rats. *J Obstet Gynaecol Res* 2021;47:2692–704.
- Akköşe Ş, Armağan E, Bulut M, Çebiçi H. Hızlı entübasyon protokolünde etomidat tek başına yeterli mi? *Acil Tıp Dergisi* 2001;1:1–4.
- Li R, Fan L, Ma F, Cao Y, Gao J, Liu H, et al. Effect of etomidate on the oxidative stress response and levels of inflammatory factors from ischemia-reperfusion injury after tibial fracture surgery. *Exp Ther Med* 2017;13:971–5.
- Zhao X, Kuang F, You YY, Wu MM, You SW. Etomidate affects the antioxidant pathway to protect retinal ganglion cells after optic nerve transection. *Neural Regen Res* 2019;14:2020–4.
- Xie D, Li M, Yu K, Lu H, Chen Y. Etomidate alleviates cardiac dysfunction, fibrosis and oxidative stress in rats with myocardial ischemic reperfusion injury. *Ann Transl Med* 2020;8:1181.
- Jia L, Hao H, Wang C, Wei J. Etomidate attenuates hyperoxia-induced acute lung injury in mice by modulating the Nrf2/HO-1 signaling pathway. *Exp Ther Med* 2021;22:785.
- Yu Q, Zhou Q, Huang H, Wang Y, Tian S, Duan D. Protective effect of etomidate on spinal cord ischemia-reperfusion injury induced by aortic occlusion in rabbits. *Ann Vasc Surg* 2010;24:225–32.

DENEYSEL ÇALIŞMA - ÖZ

Etomidat ratlarda over iskemi-reperfüzyon hasarını hafifletir

Vildan Kölükçü,¹ Mehtap Gürler Balta,¹ Hakan Tapar,¹ Tuğba Karaman,¹ Serkan Karaman,¹ Velid Unsal,² Fikret Gevrek,³ Muzaffer Katar⁴

¹Tokat Gaziosmanpaşa Üniversitesi Tıp Fakültesi, Anestezi ve Reanimasyon Anabilim Dalı, Tokat, Türkiye

²Mardin Artuklu Üniversitesi, Sağlık Bilimleri Fakültesi ve Merkezi Araştırma Laboratuvarı, Mardin, Türkiye

³Tokat Gaziosmanpaşa Üniversitesi Tıp Fakültesi, Histoloji ve Embriyoloji Anabilim Dalı, Tokat, Türkiye

⁴Tokat Gaziosmanpaşa Üniversitesi Tıp Fakültesi, Biyokimya Anabilim Dalı, Tokat, Türkiye

AMAÇ: Deneysel over iskemi reperfüzyon hasarında etomidat'ın oksidatif hasara koruyucu etkisini araştırmayı amaçladık.

GEREÇ VE YÖNTEM: Toplam 24 dişi rat üç gruba randomize edildi. Grup 1 kontrol grubu olarak atandı. Grup 2'ye over torsiyon/detorsiyon modeli uygulandı. Grup 3'te Grup 2'deki sıçanlara benzer prosedürler uygulandı. Ayrıca Grup 3'te over detorsiyonundan 30 dakika önce 4 mg/kg etomidate intraperitoneal olarak uygulandı. Kan örnekleri alınarak lipid peroksidasyon düzeyi, proinflatuvar sitokin seviyesi ve antioksidan enzim aktivitesi değerlendirildi. Ek olarak over dokusundaki hasar histopatolojik olarak skorlandı.

BULGULAR: Kan örneklerinin biyokimyasal analizinde, interlökin-1 beta (IL-1beta), interlökin-6 (IL-6) ve tümör nekroz faktör-alfa (TNF-alfa) dahil olmak üzere proinflatuvar sitokinlerin düzeylerinde Grup 3'de Grup 2'ye göre azalma olduğunu gözlemlendi (sırasıyla 0.005, p: 0.016 ve p<0.001). Benzer şekilde malondialdehit (MDA) düzeyinde de Grup 3'de Grup 2'ye göre azalma olduğu belirlendi (p<0.001). Süperoksit dismutaz (SOD) ve glutatyon peroksidaz (GSH-PX) dahil antioksidan enzim aktivitesinde ise Grup 3'de Grup 2'ye göre ciddi düzeyde artış izlendi (sırasıyla p: 0.031 ve p: 0.001). Ayrıca Grup 3; Grup 2 ile karşılaştırıldığında foliküler dejenerasyon, damar tıkanıklığı, kanama ve inflamasyon dahil histopatolojik skorlarda anlamlı bir azalma vardı (sırasıyla p<0.001, p<0.001, p<0.001 ve p: 0.001).

SONUÇ: Etomidat, rat over torsiyon/detorsiyon modelinde histopatolojik ve biyokimyasal bulguları iyileştirerek iskemi reperfüzyon hasarını hafifletmektedir.

Anahtar sözcükler: Etomidat; iskemi reperfüzyon hasarı; oksidatif stres; over torsiyon ve detorsiyon.

Ulus Travma Acil Cerrahi Derg 2024;30(5):375-381 DOI: 10.14744/tjtes.2024.27388