

Effects of ketamine on penile tissues in an experimental priapism model in rats

¹ Vildan Kölükçü, ¹ Mehtap Gürler Balta, ¹ Hakan Tapar, ¹ Tugba Karaman, ¹ Serkan Karaman, ² Velid Unsal, ² Fikret Gevrek, ³ Kenan Yalçın, ⁴ Fatih Fırat

¹Department of Anesthesiology and Reanimation, Tokat Gaziosmanpaşa University Faculty of Medicine, Tokat-Türkiye

²Mardin Artuklu University, Faculty of Health Sciences and Central Research Laboratory, Mardin-Türkiye

³Department of Histology and Embryology, Tokat Gaziosmanpaşa University Faculty of Medicine, Tokat-Türkiye

⁴Department of Urology, Tokat Gaziosmanpaşa University Faculty of Medicine, Tokat-Türkiye

ABSTRACT

BACKGROUND: This study aimed to evaluate the histopathological and biochemical effects of ketamine on penile tissues following ischemia-reperfusion injury induced by priapism.

METHODS: Twenty-four male rats were randomized into three groups. Group 1 served as the control group. Group 2 underwent the priapism model to induce ischemia-reperfusion injury. Group 3, the treatment group, experienced a similar ischemia-reperfusion model as Group 2; additionally, 50 mg/kg of ketamine was administered intraperitoneally just before reperfusion. Blood biochemical analyses and penile histopathological evaluations were performed.

RESULTS: In Group 3, significant improvements were observed in all histopathological scores, including desquamation, edema, inflammation, and vasocongestion compared to Group 2 ($p<0.001$). Blood biochemical analyses showed that the malondialdehyde (MDA) levels were recorded as 10 in Group 2, with a significant decrease in Group 3 ($p=0.013$). Similarly, proinflammatory cytokine levels, including interleukin-1 beta (IL-1 β), interleukin-6 (IL-6), and tumor necrosis factor-alpha (TNF- α), were found to be suppressed in Group 3 compared to Group 2 ($p=0.003$, $p=0.022$, and $p=0.028$, respectively). Antioxidant enzyme activities, such as glutathione peroxidase (GSH-Px) and superoxide dismutase (SOD), were higher in Group 3 compared to Group 2 ($p=0.016$ and $p=0.024$, respectively).

CONCLUSION: Ketamine is an effective anesthetic agent in alleviating the effects of penile ischemia-reperfusion injury.

Keywords: Anesthesia; ischemia-reperfusion; ketamine; penis.

INTRODUCTION

Priapism is an uncontrollable erection that does not subside with ejaculation and persists for more than four hours, irrespective of sexual stimulation. Ischemic priapism, which represents a compartment syndrome in the penis, accounts for 95% of all priapism cases. Stasis in the corpus cavernosum occurs secondary to venous obstruction. As a result, hypoxia, hypercapnia, and acidosis develop in the penile tissue

due to circulatory disorders. This condition constitutes a true urological emergency, where early intervention is crucial for functional recovery. However, reactive oxygen radicals (ROS), produced by excessive and sudden oxygenation of the environment following detumescence in erectile tissue, damage important molecules such as membrane lipids, intracellular structural proteins, and functional proteins. This paradoxically causes ischemia-reperfusion injury. In this context, minimizing

Cite this article as: Kölükçü V, Gürler Balta M, Tapar H, Karaman T, Karaman S, Unsal V, et al. Effects of ketamine on penile tissues in an experimental priapism model in rats. *Ulus Travma Acil Cerrahi Derg* 2024;30:309-315.

Address for correspondence: Vildan Kölükçü

Department of Anesthesiology and Reanimation, Tokat Gaziosmanpaşa University Faculty of Medicine, Tokat, Türkiye

E-mail: vildankolukcu@gmail.com

Ulus Travma Acil Cerrahi Derg 2024;30(5):309-315 DOI: 10.14744/tjtes.2024.33262

Submitted: 22.01.2024 Revised: 30.03.2024 Accepted: 11.04.2024 Published: 13.05.2024

OPEN ACCESS This is an open access article under the CC BY-NC license (<http://creativecommons.org/licenses/by-nc/4.0/>).



the effects of ischemia-reperfusion injury is extremely critical to prevent sexual dysfunction after priapism treatment.^[1]

Ketamine, an N-methyl-D-aspartate (NMDA) receptor antagonist and dissociative anesthetic agent,^[2] is particularly favored by anesthetists for anesthesia induction and sedation, especially in patients with circulatory insufficiency due to its effects on the sympathetic nervous system.^[3] Furthermore, it has been observed that ketamine reduces ischemia-reperfusion injury in various tissues such as skeletal muscle, kidney, intestine, and heart by inhibiting lipid peroxidation, oxidative stress, and inflammation.^[2-6]

In this experimental study, we aimed to evaluate the potential beneficial effects of ketamine on ischemia-reperfusion injury in penile tissue. To the best of our knowledge, this is the first study to administer ketamine in a rat-induced priapism model in the English literature.

MATERIALS AND METHODS

Experimental Animals and Laboratory Environment Approval was obtained from our university's local ethics committee (2023 HADYK-08) for all experimental procedures, blood analyses, and tissue examinations. For this study, 24 male Albino-Wistar rats (220-405 g) were used. The experiment was conducted under a 12-hour light/dark cycle at a constant temperature ($22\pm2^{\circ}\text{C}$). Experimental animals were observed in the laboratory in accordance with the National Research Council's Guide for the Care and Use of Laboratory Animals. Formation of Experimental Groups and Surgical Procedure All surgical procedures were performed under sterile conditions and anesthesia. For this purpose, 40 mg/kg of thiopental was administered intraperitoneally to the rats. Rats were randomized into three groups.^[7]

Group 1 was the control group. Blood samples were collected from the inferior vena cava of the rats in this group for basal biochemical and histopathological analyses, and penectomy was performed.

Group 2 was designated as the ischemia-reperfusion group. The model was performed in accordance with its previously described form in the literature. A 16 Fr Foley catheter was cut to an approximate length of 2 mm to create constriction bands. Full penile erection was induced by creating negative pressure on the rat penises with a 50-cc syringe. Constriction bands were then placed at the root of the penis to create a priapism model. After maintaining priapism for a total of one hour, the constriction bands were removed. A one-hour waiting period followed to assess ischemia-reperfusion injury.^[7] At the end of the second hour, blood samples were collected from the inferior vena cava, and penectomy was performed (Figures 1 and 2).

Group 3 was the treatment group. A similar procedure to that in Group 2 was applied. Additionally, a single dose of 50 mg/kg ketamine was administered intraperitoneally to this group after the termination of priapism and the application of constriction bands.^[8] At the end of the experiment, penectomy was performed for histopathological examination, and blood samples were collected from the inferior vena cava for biochemical analysis. After all procedures were completed, rats were euthanized by cervical dislocation.

Histopathologic Examination

Rat penis tissues were fixed in 4% buffered neutral formalin solution for three days. After routine histological processing, the tissues were embedded in paraffin blocks longitudinally and sectioned. Successive thin serial sections of 5 μm thickness were taken from the paraffin-embedded penises using a rotary microtome (Leica RM2135, Germany) and placed on slides. The penile tissue sections were then stained according to the hematoxylin-eosin staining protocol and prepared for histopathological evaluations. Hematoxylin-eosin-stained penis tissue sections were analyzed with a research light microscope (Nikon Eclipse 200; Japan). For histopathological analysis, tissue sections were evaluated and scored categorically for vasocongestion, inflammation, desquamation, and edema. Each parameter's severity of tissue damage was graded semi-quantitatively from 0 to 3 (Grade 0: Normal, Grade 1: Mild,

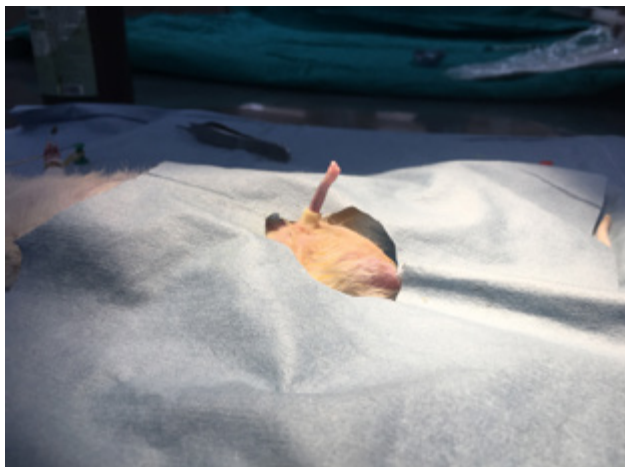


Figure 1. Experimental priapism model in a rat.

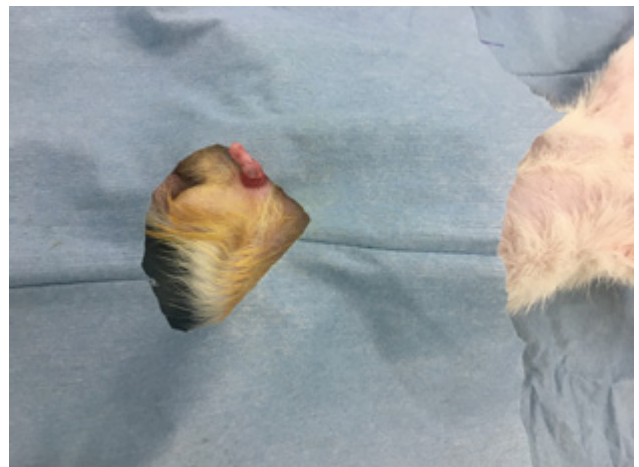


Figure 2. Penile ischemia-reperfusion injury.

Grade 2: Moderate, Grade 3: Severe). Analyses were conducted as a blind study using a coding system.^[1]

Biochemical Analyses

Collected blood samples were placed into tubes and centrifuged at 4000 rpm for 10 minutes at 4°C. The obtained serum was then frozen and stored at -20°C for the biochemical analyses listed below. Commercial and analytical grade chemical materials (Merck, Sigma-Aldrich, Tekkim, Acros Organics B.V.B.A., Alfa Aesar, and Isolab) were provided for the examination of the following parameters:

Superoxide Dismutase (SOD) Activity: This was determined based on the inhibition of nitroblue tetrazolium reduction by the xanthine-xanthine oxidase system, which serves as a superoxide radical generator. The absorbance of the formed colored formazone at 560 nm was measured.^[9] The unit U/mL was used in our study to quantify SOD activity, which involves converting reduced glutathione (GSH) added to the reaction medium into oxidized glutathione (GSSG).

Glutathione Peroxidase (GSH-Px) Activity: The activity was measured through an enzymatic reaction initiated by the addition of H2O2 to a reaction mixture containing reduced glutathione, nicotinamide adenine dinucleotide phosphate, and glutathione reductase.^[10] The activity was analyzed and quantified in U/L.

Malondialdehyde (MDA) Levels: MDA reacts with thiobarbituric acid at 90-100°C to form a pink-colored chromogen with another thiobarbituric acid-reactive substance (TBARS). After 15 minutes, the absorbance of the rapidly cooled samples was spectrophotometrically read at 532 nm and MDA

levels were measured.^[11] The unit µmol/mL was used in our study to measure MDA levels.

Interleukin-1 Beta (IL-1β), Interleukin-6 (IL-6), and Tumor Necrosis Factor-Alpha (TNF-α) Levels: Commercial Enzyme-Linked Immunosorbent Assay (ELISA) kits were purchased to measure interleukin-1 beta (IL-1β), interleukin-6 (IL-6), and tumor necrosis factor-alpha (TNF-α) in serum. The levels of TNF-α, IL-1β, and IL-6 were determined by the ELISA method as explained in the prospectuses provided with the kits. The units ng/dL, µg/dL, and ng/L were used for TNF-α, IL-1β, and IL-6 levels, respectively.

Statistical Analysis

Descriptive statistics were used to provide information about the general characteristics of the study groups. Data for the variables were described using mean ± standard deviation and range (min-max). Differences between groups in variables were assessed using One-Way Analysis of Variance (ANOVA). Post-hoc Tukey's Honestly Significant Difference (HSD) or Tamhane's T2 tests were used for further comparisons. P-values were considered statistically significant when calculated to be below 0.05. Ready-to-use statistical software was employed for the analyses (IBM Statistical Package for the Social Sciences (SPSS) Statistics 22, SPSS Inc., IBM Co., Somers, NY).

RESULTS

Histopathological Findings

Our histopathological results are detailed in Table 1. Intense inflammatory cell infiltration was observed in Group 2 compared to the other groups. In Group 3, inflammation was ob-

Table 1. Comparison of histopathological scores of penile damage between groups

	Group	n	Mean±SD	Min-Max	p-values	Post Hoc p-values
Desquamation	1	8	0.19±0.07	0.13-0.33	<0.001*	1-2: <0.001*
	2	8	1.97±0.25	1.53-2.32		1-3: <0.001*
	3	8	0.97±0.27	0.45-1.34		2-3: <0.001*
Edema	1	8	0.24±0.08	0.11-0.36	<0.001*	1-2: <0.001*
	2	8	2.24±0.3	1.9-2.64		1-3: <0.001*
	3	8	1.05±0.25	0.5-1.35		2-3: <0.001*
Inflammation	1	8	0.13±0.04	0.05-0.18	<0.001*	1-2: <0.001*
	2	8	2.03±0.12	1.92-2.22		1-3: <0.001*
	3	8	1.13±0.17	0.84-1.31		2-3: <0.001*
Vasocongestion	1	8	0.31±0.08	0.17-0.44	<0.001*	1-2: <0.001*
	2	8	2.36±0.24	2.08-2.69		1-3: <0.001*
	3	8	1.04±0.17	0.88-1.3		2-3: <0.001*
Total	1	8	0.87±0.17	0.66-1.14	<0.001*	1-2: <0.001*
	2	8	8.59±0.83	7.43-9.62		1-3: <0.001*
	3	8	4.19±0.66	3.05-4.98		2-3: <0.001*

Test: One-Way Analysis of Variance (ANOVA). (Differences between groups were examined using Post Hoc Tukey HSD or Tamhane's T2 tests.) *Statistically significant (p<0.05).

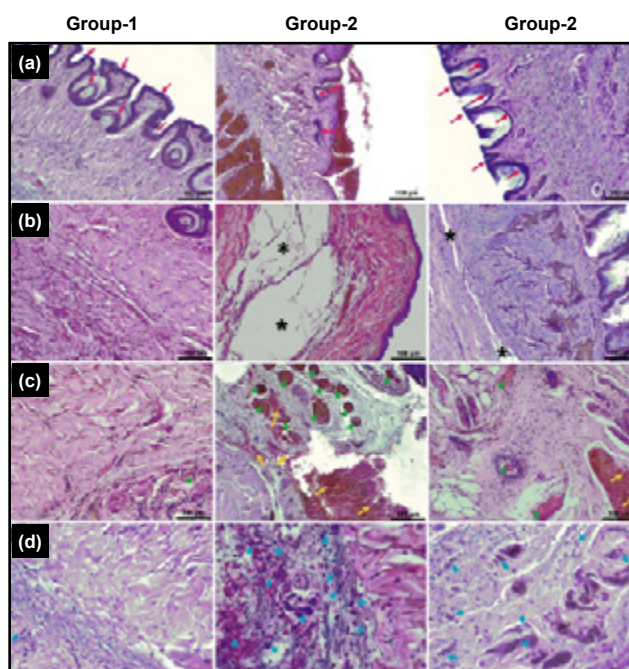


Figure 3. Representative microscopic images of penises from each study group with hematoxylin-eosin stain. Images in row (a) are evaluations of desquamation (red arrows indicate epithelium). Epithelial appearance of normal thickness in Group 1. Marked desquamation, with epithelium visible only in the basal layer, in Group 2. Mild desquamation was detected in Group 3. Images in row (b) are comparisons of edema (asterisk indicates areas of edema). There is no edema in Group 1. Marked and diffuse edema in Group 2. Mild edema in Group 3. Images in row (c) are comparisons of vasocongestion and hemorrhage (green arrowhead indicates vasocongestion; yellow arrow indicates hemorrhagic areas). Normal stromal areas with normal caliber vascular structures in Group 1. Intense vasocongestion and severe hemorrhagic areas in Group 2. Mild to moderate vasocongestion and hemorrhagic areas in Group 3. Images in row (d) are comparisons of inflammation (blue arrowhead indicates areas of inflammatory cell infiltration). There is no inflammatory cell infiltration in Group 1. Areas of intense inflammatory cell infiltration in Group 2. Mild to moderate inflammatory cell infiltration areas in Group 3. (Scale bars: 100 μ m for rows A, B, and C; 50 μ m for row D).

served to be suppressed compared to Group 2 ($p<0.001$). Similarly, a significant decrease in desquamation, edema, and vasocongestion scores was noted in Group 3 compared to Group 2 ($p<0.001$). The total histopathological damage score was calculated as 8.59 in Group 2, while a dramatic improvement was reported in Group 3 with a score of 4.19 ($p<0.001$) (Fig. 3).

Biochemical Findings

In our biochemical analyses, IL-1 β , IL-6, and TNF- α proinflammatory cytokine levels in Group 2 were significantly higher compared to Group 1 ($p<0.001$, $p=0.003$, and $p=0.001$, respectively). In Group 3, a dramatic decrease was observed in the levels of these proinflammatory cytokines ($p=0.003$, $p=0.022$, and $p=0.028$, respectively). The level of MDA, the

end product of lipid peroxidation, was noted as 10 in Group 2. In Group 3, this value was recorded as 6.4, indicating a lower level than in Group 2 ($p=0.013$). The levels of antioxidant enzymes, SOD and GSH-Px, in Group 3 were significantly increased compared to Group 2 ($p=0.024$ and $p=0.016$) (Table 2).

DISCUSSION

Ischemic priapism is the most common form of priapism, with an incidence of 0.3 to 0.9 cases per 100,000 person-years. It is caused by an imbalance between vasoconstrictive and vasorelaxative mechanisms in the penile tissue.^[12] Due to veno-occlusion, oxidative phosphorylation is impaired in the penile tissue, resulting in intracellular adenosine triphosphate (ATP) levels falling below the threshold necessary for cell survival.^[13] Ultrastructural changes in cavernosal smooth muscle manifest as interstitial edema after 12 hours, while sinusoidal endothelial cell damage occurs up to 24 hours. If the stasis condition persists, smooth muscle necrosis and fibroblast-like cells significantly dominate the environment by the second day of priapism.^[1] Treating priapism by terminating venous stasis is critical for the viability of erectile tissues. Additionally, with the termination of priapism, the corpus cavernosum is exposed to high oxygen concentrations as oxygenated blood re-enters the penile tissue. This influx causes excessive levels of reactive oxygen species (ROS) to rise. On the other hand, the sodium-potassium ATPase pump is inhibited due to the decreasing level of high-energy molecules in the ischemic tissue, leading to increased intracellular sodium and calcium ion concentrations. This shift activates inflammation and suppresses antioxidant enzyme levels.^[13] The weakened antioxidant defense systems are ineffective against the sudden increase in ROS, thus triggering a chain of reactions known as ischemia-reperfusion injury, which has devastating effects on vital cellular components in the re-oxygenated penile tissue.^[1]

During the ischemia period, a dramatic increase in the levels of purine metabolites such as adenosine, hypoxanthine, xanthine and inosine—by-products of ATP catabolism—is observed. With the restoration of blood circulation, these molecules become unstable by utilizing oxygen as an oxidant, and ROS are intensively formed.^[14] Ischemia-reperfusion injury leads to the generation of a significant amount of ROS, resulting in numerous harmful effects such as lipid peroxidation, polysaccharide polymerization, and genomic structural damage.^[1,13] In the experimental model of Munarriz et al., a significant increase in polymorphonuclear leukocytes infiltration, myeloperoxidase activity, and lipid peroxidase level was reported due to reperfusion injury in the cavernosal tissue.^[12] In the study by Yilmaz et al., it was noted that cavernosal ischemia-reperfusion injury led to an increase in total oxidant status and a suppression of total antioxidant status; additionally, direct microscopic examination revealed increased scores for hemorrhage, edema, and necrosis.^[13] In our study, significant increases in desquamation, edema, inflammation,

Table 2. Comparison of SOD and GSH-Px activities, TNF- α , IL-1 β , IL-6, and MDA levels obtained from blood between rat groups

	Group	n	Mean \pm SD	Min-Max	p-values	Post Hoc p-values
SOD (U/ml)	1	8	9.56 \pm 1.74	5.98-11.2	0.002*	1-2: 0.001*
	2	8	6.38 \pm 1.64	4.2-8.23		1-3: 0.64
	3	8	7.81 \pm 1.03	5.7-8.9		2-3: 0.024*
GSH-PX (U/L)	1	8	576.15 \pm 128.43	388.9-786.3	0.002*	1-2: 0.009*
	2	8	357.74 \pm 116.44	224.1-500.1		1-3: 0.040*
	3	8	438.06 \pm 54.28	365.3-551.1		2-3: 0.016*
MDA (μ mol/mL)	1	8	4.5 \pm 2.41	1.9-8.02	<0.001*	1-2: <0.001*
	2	8	10 \pm 2.43	6.11-13.32		1-3: 0.063
	3	8	6.4 \pm 1.97	4.01-10.03		2-3: 0.013*
TNF- α (ng/dL)	1	8	33.61 \pm 14.2	17.2-62.1	0.002*	1-2: 0.001*
	2	8	65.2 \pm 12.25	41.2-78.4		1-3: 0.058
	3	8	43.65 \pm 18.93	20-70.1		2-3: 0.028*
IL-1 β (μ g/dL)	1	8	2.04 \pm 0.38	1.8-3.01	<0.001*	1-2: <0.001*
	2	8	3.47 \pm 0.55	2.8-4.2		1-3: 0.059
	3	8	2.4 \pm 0.74	1.7-3.7		2-3: 0.003*
IL-6 (ng/L)	1	8	21.83 \pm 6.78	11.2-31.2	0.003*	1-2: 0.003*
	2	8	35.98 \pm 5.53	27.8-41.9		1-3: 0.061
	3	8	25.07 \pm 9.58	5.88-38.3		2-3: 0.022*

Abbreviations: GSH-Px: Glutathione Peroxidase; IL-1 β : Interleukin 1 Beta; IL-6: Interleukin 6; MDA: Malondialdehyde; SD: Standard Deviation; SOD: Superoxide Dismutase; TNF- α : Tumor Necrosis Factor Alpha. Test: One-Way Analysis of Variance (ANOVA). (Differences between groups were examined using Post Hoc Tukey HSD or Tamhane's T2 tests.). *Statistically significant (p<0.05).

and vasocongestion levels in penile tissue due to ischemia-reperfusion injury were observed. Furthermore, increases in the levels of proinflammatory cytokines and lipid peroxidation were noted.

Reoxygenation of hypoxic erectile tissue presents deleterious oxidative stress in the corpus cavernosum.^[12] Increased oxidative stress leads to structural changes in cell membranes and irreversible cellular damage, facilitated by elevated levels of ROS in the systemic circulation.^[15] Therefore, the increased level of oxidative stress in priapism is directly related to erectile dysfunction. Clinical studies have reported that the increase in oxidative stress in patients with priapism could be a key determinant for subsequent sexual dysfunction in 44-90% of these patients.^[16] In this context, minimizing oxidative stress in patients with priapism is critical for maintaining a healthy sexual life. Cases of priapism often present to emergency clinics with painful erections. The treatment algorithms for priapism include invasive methods such as penile aspiration or shunt applications.^[14] Thus, analgesia plays a significant role in the management of these patients. We consider it crucial to document that ketamine, commonly used in medical practice for its analgesic and anesthetic effects, minimizes penile oxidative stress in our rat model of priapism, as this could guide future clinical studies.

Ketamine, a derivative of N-1 phenylcyclohexypiperidine,

was first synthesized in 1962.^[17,18] It provides loss of consciousness, amnesia, immobility, and deep analgesia during anesthesia.^[18] While ketamine is renowned for its anesthetic properties, recent clinical and experimental studies have also highlighted its tissue-protective effects against oxidative damage. It exerts these protective effects in various ways, including suppressing inflammation, activating glutathione peroxidase, inhibiting lipid peroxidation, directly scavenging ROS, and neutralizing them. In a clinical study involving 30 cases, Saricaoglu et al. reported that administering ketamine during arthroscopic knee surgeries with tourniquet application reduced levels of malondialdehyde and hypoxanthine in synovial tissue, thereby inhibiting lipid peroxidation associated with ischemia-reperfusion injury.^[19] In a similar clinical study, Peker et al. reported that ketamine exhibited protective activity in skeletal muscle ischemia-reperfusion injury by reducing lactate and ischemia-altered albumin levels.^[2] Salman et al. also reported that ketamine reduced lipid peroxidation and protected against oxidative damage in a skeletal muscle ischemia-reperfusion model.^[20] In another experimental study, Demirkan et al. found that in a renal ischemia-reperfusion rat model, ketamine increased antioxidant status parameters such as superoxide dismutase and glutathione peroxidase, while it suppressed levels of proinflammatory biomarkers such as TNF- α , IL-1 β , and IL-6, thus reducing tissue damage markers like nitric oxide and malondialdehyde.^[4] Similarly,

our study determined that ketamine caused an increase in antioxidant enzyme levels and a decrease in lipid peroxidation levels. Additionally, it was found that ketamine improves edema, congestion, and hemorrhage scores that develop secondary to penile ischemia-reperfusion injury.

These anti-inflammatory properties of ketamine have been examined biochemically and histopathologically in recent experimental studies. The key findings of these studies indicate that ketamine is highly effective as an anesthetic, reducing proinflammatory cytokine levels (IL-1, IL-6, IL-8, and TNF- α), neutrophil adhesion and migration, while inhibiting free radical release and blocking nitric oxide production by macrophages.^[5,21] In their experimental studies, Xingwei et al. reported that ketamine treatment showed protective activity against oxidative damage by suppressing the inflammatory response caused by CO₂ pneumoperitoneum.^[22] In their study, Taniguchi et al. created an endotoxin-induced shock model in rats and reported that ketamine treatment inhibited hypotension, metabolic acidosis, and cytokine responses, which increased the survival rates of the experimental animals.^[4] In an experimental study assessing the intestinal ischemia-reperfusion model, it was observed that the administration of ketamine inhibited leukocyte infiltration, regulated adhesion molecule-I and serum antithrombin-III levels, and accordingly led to an improvement in the adverse effects of ischemia-reperfusion.^[23] In another experimental study, Wang et al. reported that ketamine had positive effects against ischemia-reperfusion injury following liver autotransplantation in rats by suppressing the activation of Kupffer cells.^[24] In our study, intense inflammatory cell infiltration observed in the corpus cavernosum secondary to penile ischemia-reperfusion injury was histopathologically documented to be suppressed by ketamine administration. Additionally, ketamine was observed to cause a significant decrease in IL-1, IL-6, and TNF- α levels, which increase dramatically with ischemia-reperfusion injury.

Limitations of This Study

The limitations of our study are that the effects of ketamine were analyzed in penile tissue samples using only a single technique, hematoxylin-eosin staining, and the long-term effects of ketamine on corporal tissue could not be evaluated.

CONCLUSION

According to the data obtained in our study, ketamine shows protective activity against penile ischemia-reperfusion injury by increasing antioxidant enzyme levels and suppressing inflammation. Minimizing penile ischemia-reperfusion injury in cases of priapism is very important for maintaining optimal sexual health in the future. In this context, we believe that supporting our study with randomized clinical studies will make valuable contributions to the discipline of andrology in the future.

Ethics Committee Approval: This study was approved by the Tokat Gaziosmanpaşa University Faculty of Medicine Eth-

ics Committee (Date: 12.06.2023, Decision No: 51879863-29).

Peer-review: Externally peer-reviewed.

Authorship Contributions: Concept: V.K., S.K., M.G.B., T.K., F.F., K.Y., H.T., V.U.; Design: V.K., M.G.B., F.F., H.T., V.U.; Supervision: V.K., T.K., H.T., S.K., K.Y.; Resource: V.K., F.G., V.U., T.K., F.F.; Materials: V.K., F.F., J.K. T.K., M.G.B., H.T.; Data collection and/or processing: V.K., V.U., H.T., F.G., F.F.; Analysis and/or interpretation: V.K., V.U., H.T., T.K., S.K., F.F., K.Y., F.G.; Literature search: T.K., V.K., H.T., S.K., V.U.; Writing: S.K., F.F., V.U., K.Y., F.G.; Critical review: V.K., T.K., M.G.B., H.T.

Conflict of Interest: None declared.

Use of AI for Writing Assistance: Not declared.

Financial Disclosure: The author declared that this study has received no financial support.

REFERENCES

- Kölükçü E, Parlaktaş BS, Kölükçü V, Firat F, Deresoy FA, Katar M, et al. Protective effects of dexmedetomidine on ischaemia-reperfusion injury in an experimental rat model of priapism. *Andrologia* 2021;53:e13985.
- Peker K, Ökesli S, Kırıncı A, Deyişli C. The effects of ketamine and lidocaine on free radical production after tourniquet-induced ischemia-reperfusion injury in adults. *Ulus Travma Acil Cerrahi Derg* 2019;25:111-7.
- Taniguchi T, Takemoto Y, Kanakura H, Kidani Y, Yamamoto K. The dose-related effects of ketamine on mortality and cytokine responses to endotoxin-induced shock in rats. *Anesth Analg* 2003;97:1769-72.
- Demirkiran H, Senoglu N, Oksuz H, Doğan Z, Yuzbaioğlu F, Bulbuloglu E, et al. The effects of different doses of ketamine on renal ischemia/reperfusion injury in rats. *East J Med* 2019;24:194-9.
- Cámara CR, Guzmán FJ, Barrera EA, Cabello AJ, García A, Fernández NE, et al. Ketamine anesthesia reduces intestinal ischemia/reperfusion injury in rats. *World J Gastroenterol* 2008;14:5192-6.
- Roytblat L, Talmor D, Rachinsky M, Greemberg L, Pekar A, Appelbaum A, et al. Ketamine attenuates the interleukin-6 response after cardiopulmonary bypass. *Anesth Analg* 1998;87:266-71.
- Ergün Y, Oksüz H, Atli Y, Kiliç M, Darendeli S. Ischemia-reperfusion injury in skeletal muscle: Comparison of the effects of subanesthetic doses of ketamine, propofol, and etomidate. *J Surg Res* 2010;159:e1-10.
- Guzmán-de la Garza FJ, Cámara-Lemarroy CR, Ballesteros-Elizondo RG, Alarcón-Galván G, Cordero-Pérez P, Fernández-Garza NE. Ketamine and the myenteric plexus in intestinal ischemia/reperfusion injury. *Dig Dis Sci* 2010;55:1878-85.
- Sun Y, Oberley LW, Li Y. A simple method for clinical assay of superoxide dismutase. *Clin Chem* 1988;34:497-500.
- Paglia DE, Valentine WN. Studies on the quantitative and qualitative characterization of erythrocyte glutathione peroxidase. *J Lab Clin Med* 1967;70:158-69.
- Esterbauer H, Cheeseman KH. Determination of aldehydic lipid peroxidation products: Malonaldehyde and 4-hydroxynonenal. *Methods Enzymol* 1990;186:407-21.
- Munarriz R, Park K, Huang YH, Saenz de Tejada I, Moreland RB, Goldstein I, et al. Reperfusion of ischemic corporal tissue: Physiologic and biochemical changes in an animal model of ischemic priapism. *Urology* 2003;62:760-4.
- Yılmaz Y, Taken K, Atar M, Ergün M, Söylemez H. Protective effect of curcumin on priapism and ischemia-reperfusion injury in rats. *Eur Rev Med Pharmacol Sci* 2015;19:4664-70.
- Kölükçü E, Parlaktaş BS, Uluocak N, Deresoy FA, Katar M, Unsal V. Dapsone can be a new treatment option for reducing the detrimental ef-

- fect of priapism. *J Health Sci Med* 2021;4:800–8.
15. Kucukdurmaz F, Kucukgergin C, Akman T, Salabas E, Armagan A, Seckin S, et al. Duration of priapism is associated with increased corporal oxidative stress and antioxidant enzymes in a rat model. *Andrologia* 2016;48:374–9.
 16. Kanika ND, Melman A, Davies KP. Experimental priapism is associated with increased oxidative stress and activation of protein degradation pathways in corporal tissue. *Int J Impot Res* 2010;22:363–73.
 17. Cui L, Jiang X, Zhang C, Li D, Yu S, Wan F, et al. Ketamine induces endoplasmic reticulum stress in rats and SV-HUC-1 human uroepithelial cells by activating NLRP3/TXNIP axis. *Biosci Rep* 2019;39:BSR20190595.
 18. Kasikara H, Sungu N, Arslan M, Kucuk A, Ozturk L, Afandiyeva N, et al. Repeated doses of ketamine affect the infant rat urogenital system. *Drug Des Devel Ther* 2021;15:1157–65.
 19. Saricaoglu F, Dal D, Salman AE, Doral MN, Klnç K, Aypar Ü. Ketamine sedation during spinal anesthesia for arthroscopic knee surgery reduced the ischemia-reperfusion injury markers. *Anesth Analg* 2005;101:904–9.
 20. Salman AE, Dal D, Salman MA, Iskit AB, Aypar U. The effect of ketamine on acute muscular ischaemia reperfusion in rats. *Eur J Anaesthesiol* 2005;22:712–6.
 21. Gundogdu Z, Demirel I, Bayar MK, Ozkan Z, Bayindir S, Kocyigit F, et al. Dose-dependent anti-inflammatory effect of ketamine in liver ischemia-reperfusion injury. *Middle East J Anaesthesiol* 2016;23:655–63.
 22. Xingwei X, Xin G, Peng Z, Tao F, Bowen D, Xiaoming K, et al. Low-dose ketamine pretreatment reduces oxidative damage and inflammatory response following CO₂ pneumoperitoneum in rats. *Clin Invest Med* 2014;37:E124.
 23. Guzmán-De La Garza FJ, Cámara-Lemarroy CR, Ballesteros-Elizondo RG, Alarcón-Galván G, Cordero-Pérez P, Fernández-Garza NE. Ketamine reduces intestinal injury and inflammatory cell infiltration after ischemia/reperfusion in rats. *Surg Today* 2010;40:1055–62.
 24. Li X, Wang J, Song X, Wu H, Guo P, Jin Z, et al. Ketamine ameliorates ischemia-reperfusion injury after liver autotransplantation by suppressing activation of Kupffer cells in rats. *Can J Physiol Pharmacol* 2018;96:886–92.

DENEYSEL ÇALIŞMA - ÖZ

Ratlarda deneysel priapizm modelinde ketamin'in penil dokular üzerine etkileri

Vildan Kölükçü,¹ Mehtap Gürlür Balta,¹ Hakan Tapar,¹ Tugba Karaman,¹ Serkan Karaman,¹ Velid Unsal,² Fikret Gevrek,³ Kenan Yalçın,⁴ Fatih Fırat⁴

¹Tokat Gaziosmanpaşa Üniversitesi Tıp Fakültesi, Anestezi Ve Reanimasyon Anabilim Dalı, Tokat, Türkiye

²Mardin Artuklu Üniversitesi, Sağlık Bilimleri Fakültesi Ve Merkezi Araştırma Laboratuvarı, Mardin, Türkiye

³Tokat Gaziosmanpaşa Üniversitesi Tıp Fakültesi, Histoloji Ve Embriyoloji Anabilim Dalı, Tokat, Türkiye

⁴Tokat Gaziosmanpaşa Üniversitesi Tıp Fakültesi, Üroloji Anabilim Dalı, Tokat, Türkiye

AMAÇ: Bu çalışmada priapizm sonrası gelişen iskemi-reperfüzyon hasarında ketamin'in penil dokular üzerindeki histopatolojik ve biyokimsiyal etkilerinin değerlendirilmesi amaçlandı.

GEREÇ VE YÖNTEM: Toplam 24 erkek rat 3 gruba randomize edildi. Grup-1 kontrol grubu olarak belirlendi. Grup-2'de priapizm modeli oluşturularak penil iskemi reperfüzyon hasarının değerlendirildiği grup olarak tanımlandı. Grup 3 ise tedavi grubu idi. Bu grupta Grup 2 ile benzer iskemi reperfüzyon modeli oluşturuldu ek olarak reperfüzyondan hemen önce 50 mg/kg ketamin intraperitoneal olarak uygulandı. Kan biyokimsiyal analizleri ve penil histopatolojik değerlendirilmesi yapıldı.

BULGULAR: Grup 3'de deskuamasyon, ödem, inflamasyon ve vazokonjesyon olmak üzere tüm histopatolojik skorlarda Grup 2'e göre dramatik olarak iyileşme gözlemlendi ($p < 0.001$). Kan biyokimsiyal analizlerinde ise MDA değeri Grup 2'de 10 olarak kayıt edildi. Bu değer Grup 3'de ciddi düzeyde azalmış olarak not edildi ($p: 0.013$). Benzer şekilde IL-1, IL-6 ve TNF-alfa olmak üzere proinflamatuvar sitokin düzeyinde Grup 3'de Grup 2'ye göre baskılanmış olarak belirlendi (sırasıyla; $p: 0.003$, $p: 0.022$ ve $p: 0.028$). Antioksidan enzim düzeyinde ise hem GSH-Px hemden SOD aktivite-tileri Grup 3'de Grup 2'ye göre artmış olarak kayıt edildi ($p: 0.016$ ve $p: 0.024$).

SONUÇ: Ketamin penil iskemi reperfüzyon hasarının etkilerini hafifletmede etkin bir anestezi-ajandır.

Anahtar sözcükler: anestezi; iskemi-reperfüzyon; ketamin; penis.

Ulus Travma Acil Cerrahi Derg 2024;30(5):309-315 DOI: 10.14744/tjtes.2024.33262