

Is there any effect of lidocaine on ischemia/reperfusion injury in testicular torsion? An experimental study

¹ Vildan Kölükçü,¹ ² Mehtap Gürlü Balta,¹ ³ Hakan Tapar,¹ ⁴ Tugba Karaman,¹ ⁵ Serkan Karaman,¹ ⁶ Velid Unsal,² ⁷ Fikret Gevrek,³ ⁸ Kenan Yalçın,⁴ ⁹ Fatih Fırat⁴

¹Department of Anesthesiology and Reanimation, Tokat Gaziosmanpaşa University Faculty of Medicine, Tokat-Türkiye

²Mardin Artuklu University, Faculty of Health Sciences and Central Research Laboratory, Mardin-Türkiye

³Department of Histology and Embryology, Tokat Gaziosmanpaşa University Faculty of Medicine, Tokat-Türkiye

⁴Department of Urology, Tokat Gaziosmanpaşa University Faculty of Medicine, Tokat-Türkiye

ABSTRACT

BACKGROUND: This experimental study aimed to evaluate the potential protective effects of lidocaine on ischemia-reperfusion injury resulting from testicular torsion/detorsion in rats.

METHODS: A total of 18 male rats were randomized into three groups. Group 1 served as the control group. Group 2 was designed to evaluate testicular ischemia-reperfusion injury using a torsion/detorsion model. In Group 3, the treatment group, a similar ischemia-reperfusion model was used as in Group 2. Additionally, lidocaine at a dose of 15 mg/kg was administered intraperitoneally five minutes before reperfusion. Blood biochemical analyses and testicular histopathological evaluations were conducted.

RESULTS: Blood biochemical analysis showed that malondialdehyde (MDA) and protein carbonyl (PC) levels were significantly higher in Group 2 compared to the other groups ($p<0.001$ and $p=0.008$, respectively). Proinflammatory cytokine levels, including interleukin-1 (IL-1), interleukin-6 (IL-6), and tumor necrosis factor-alpha (TNF-alpha), were lower in Group 3 than in Group 2 ($p<0.001$, $p=0.007$, and $p=0.026$, respectively). Antioxidant enzyme activities, including glutathione peroxidase (GSH-Px) and superoxide dismutase (SOD), were higher in Group 3 compared to Group 2 ($p=0.005$ and $p=0.025$, respectively). Histopathological evaluations revealed significant improvements in all testicular damage scores, including hemorrhage, edema, vasocongestion, and inflammation in Group 3 compared to Group 2 ($p=0.015$, $p=0.035$, $p=0.015$, and $p=0.034$, respectively). Additionally, there was a notable improvement in the Johnsen score in Group 3 compared to Group 2 ($p=0.034$).

CONCLUSION: Lidocaine, an effective local anesthetic, significantly alleviates the effects of testicular ischemia-reperfusion injury.

Keywords: Anesthesia; ischemia-reperfusion; lidocaine; testis.

INTRODUCTION

Testicles are crucial organs for healthy reproduction and sexual health. Despite various testicular pathologies such as orchitis, abscess, and benign or malignant neoplasms, testicular torsion is critically important due to its direct impact on tissue viability. Testicular torsion is a clinical condition where the spermatic cord twists, disrupting the testicular blood supply

and causing ischemia of the testicle. In treating this emergency, the most important step is to untwist the testis and restore tissue perfusion. However, when the spermatic cord is returned to its original position and testicular blood flow is re-established, reactive oxygen radicals formed by the sudden increase in oxygenation can damage vital molecules such as membrane lipids, macro proteins, and intracellular genomic

Cite this article as: Kölükçü V, Balta MG, Tapar H, Karaman T, Karaman S, Unsal V, Gevrek F, Yalçın K, Fırat F. Is there any effect of lidocaine on ischemia/reperfusion injury in testicular torsion? An experimental study *Ulus Travma Acil Cerrahi Derg* 2024;30:708-714.

Address for correspondence: Vildan Kölükçü

Department of Anesthesiology and Reanimation, Tokat Gaziosmanpaşa University Faculty of Medicine, Tokat, Türkiye

E-mail: vildankolukcu@gmail.com

Ulus Travma Acil Cerrahi Derg 2024;30(10):708-714 DOI: 10.14744/tjtes.2024.54534

Submitted: 07.05.2024 Revised: 22.08.2024 Accepted: 06.09.2024 Published: 07.10.2024

OPEN ACCESS This is an open access article under the CC BY-NC license (<http://creativecommons.org/licenses/by-nc/4.0/>).



material, paradoxically causing ischemia-reperfusion injury. In this context, minimizing the effects of ischemia-reperfusion injury is vital to ensure the reproductive health of patients with testicular torsion is not compromised post-treatment.^[1,2]

Due to its rapid onset, lidocaine is widely utilized in infiltration anesthesia, extremity blocks, topical anesthesia, and intravenous regional anesthesia in both surgical and outpatient settings.^[3] Lidocaine primarily undergoes metabolism in the liver;^[4] with a half-life of approximately 100 minutes following an infusion of less than 12 hours or a bolus. For infusions lasting longer than 12 hours, lidocaine exhibits non-linear or time-dependent pharmacokinetics.^[5] This local anesthetic, an amide derivative, not only blocks nerve signals but also exerts systemic effects such as anti-inflammatory actions, ion balance maintenance, and reactive oxygen radical scavenging.^[6,7] Previous studies have shown that lidocaine provides protection against ischemia-reperfusion injury in various organs, including the lungs, kidneys, brain, and heart, due to its antioxidative properties.^[7,8]

In this experimental study, we aimed to analyze the potential protective effect of lidocaine against testicular ischemia-reperfusion injury in a rat model of testicular torsion/detorsion. To our knowledge, this is the first experimental study in the English literature to investigate the early effectiveness of lidocaine in testicular ischemia-reperfusion injury.

MATERIALS AND METHODS

Experimental Animals and Environment All experimental interventions were approved by the Tokat Gaziosmanpaşa University Animal Experiments Local Ethics Committee (2023 HADYEK-29). Eighteen male Albino-Wistar rats, weighing 240-425 grams and aged 13-15 weeks, were included in our study. The experiments were conducted under a 12-hour light/dark cycle at a constant temperature of 22±2°C.

Formation of Experimental Groups and Surgery Procedure

All surgical procedures were conducted under sterile conditions using ketamine/xylazine anesthesia. Xylazine (Rompun 2%, Bayer, Türkiye), an anesthetic agent with sedative and muscle relaxation effects, was administered at a dose of 10 mg/kg intraperitoneally. Additionally, ketamine (Alfamine 10%, Ege Vet, Türkiye), known for its dissociative anesthetic properties, was given at a dose of 50 mg/kg intraperitoneally.^[2] A total of 18 rats were randomized into three groups:

- Group 1 served as the control group. In this group, only unilateral orchiectomy was performed. Blood samples were collected from the inferior vena cava for biochemical analysis, and testicular tissues were subjected to histopathological examination.
- Group 2 was designated as the ischemia-reperfusion group. In this group, the testicular torsion/detorsion model was performed according to the method previously described in

the literature. The unilateral testicles of the rats were accessed through a left inguinoscrotal incision, and the testicles were rotated counterclockwise by 720 degrees for 3 hours, then secured to the scrotum with 5-0 polyglactin sutures. After three hours, the testicle was detorsioned and allowed to reperfuse for another three hours. Following a total of six hours, unilateral orchiectomy was performed.^[9] Blood samples were collected from the inferior vena cava for biochemical analysis, and testicular tissues were subjected to histopathological examination procedures.

- Group 3 was established as the treatment group. This group underwent a similar testicular torsion/detorsion procedure as Group 2. Additionally, 15 mg/kg of lidocaine was administered intraperitoneally five minutes before the detorsion of the testicles.^[10] Blood samples were collected from the inferior vena cava for biochemical analysis, and testicular tissues underwent similar histopathological examination procedures as the other groups.

At the conclusion of all procedures, the rats were euthanized by cervical dislocation.

Histopathologic Examination

After orchiectomy, testicular tissues were excised and fixed in 4% buffered neutral formalin solution for two days for histological analysis. The tissues were sectioned into 4 µm slices using a microtome and stained with hematoxylin and eosin. Testicular tissues were examined under a light microscope (Nikon, Eclipse 200; Japan) at a 40x magnification. Testicular tissues were evaluated histopathologically and spermatogenically using the Johnsen scoring system, and the mean Johnsen score was calculated. Testicular parenchymal damage was assessed for hemorrhage, edema, vasocongestion, and inflammation, with scores ranging from 0 to 3 as follows: 0: normal; 1: mild; 2: moderate; and 3: severe.^[2] Additionally, the maturity of the germinal epithelial cells in the seminiferous tubules was thoroughly analyzed using the Johnsen scoring criteria, which range from 1 to 10.^[11]

Biochemical Analyses

Blood samples collected from the inferior vena cava during the establishment of experimental groups and surgical procedures were placed in tubes designated for biochemical measurements. The blood in the tubes was centrifuged at 4000 rpm at 4°C for 10 minutes, then the serum was frozen and stored at -20°C until the day of analysis. Commercial and analytical grade chemical materials (Sigma-Aldrich, Merck, Alfa Aesar, Acros Organics B.V.B.A., Tekkim, Isolab) were used for the measurement of superoxide dismutase (SOD), glutathione peroxidase (GSH-Px), malondialdehyde (MDA), and protein carbonyl (PC).

Determination of SOD Activity

SOD activity was assessed based on the inhibition of nitro-blue tetrazolium reduction by the xanthine-xanthine oxidase system, used as a superoxide radical generator.^[12] The activity

of SOD was expressed in U/mL.

Determination of GSH-Px Activity

The activity of GSH-Px was determined by its ability to convert reduced glutathione (GSH) in the reaction medium into oxidized glutathione (GSSG). This enzymatic activity was measured by initiating a reaction with the addition of hydrogen peroxide (H₂O₂) to a mixture containing reduced glutathione, nicotinamide adenine dinucleotide phosphate, and glutathione reductase.^[13] The activity of GSH-Px was expressed in U/L.

Measurement of MDA Level

MDA levels were determined using a method that involves the reaction with thiobarbituric acid at temperatures ranging from 90-100°C.^[14] The concentration of MDA was measured in µmol/mL.

Measurement of PC Level

PC levels were measured spectrophotometrically using a method based on the reaction of the carbonyl group with

2,4-dinitrophenylhydrazine (DNPH) to form a derivative.^[15] The concentration of PC was expressed in µmol/mL.

Measurement of Interleukin 1 Beta (IL-1 Beta), Interleukin 6 (IL-6), and Tumor Necrosis Factor Alpha (TNF-Alpha)

Commercial enzyme-linked immunosorbent assay (ELISA) kits (BTLab brand, China) were used to measure the levels of IL-1 beta, IL-6, and TNF-alpha in serum. The levels of these inflammatory markers were determined using the ELISA method, as described in the package inserts. In our study, units of ng/dL, µg/dL, and ng/L units were used for TNF-alpha, IL-1 beta, and IL-6 levels, respectively.

Statistical Analysis

Descriptive statistics were used to summarize the general characteristics of the study groups. Data for variables are presented as mean ± standard deviation and median (minimum-maximum). Differences between groups regarding variables were analyzed using One-Way Analysis of Variance (ANOVA) or Kruskal-Wallis Analysis of Variance following a normality

Table 1. Comparison of superoxide dismutase (SOD) and glutathione peroxidase (GSH-Px) activity, malondialdehyde (MDA), protein carbonyl (PC), interleukin-1 beta (IL-1beta), interleukin-6 (IL-6), and tumor necrosis factor-alpha (TNF-alpha) levels obtained from blood between rat groups

	Groups	N	Mean±SD	Min-Max	p-Values	Post-Hoc p-Values
SOD (U/mL)	1	6	8.4±0.76	6.93-8.99	<0.001*	1-2:<0.001*
	2	6	5.13±0.99	3.93-6.3		1-3:0.109
	3	6	7.2±1.09	5.51-8.2		2-3:0.005*
GSH-Px (U/mL)	1	6	680.19±134.39	503.2-885.3	0.002*	1-2:0.001*
	2	6	398.7±103.07	308.1-532.1		1-3:0.128
	3	6	548.83±85.05	411.1-662.1		2-3:0.025*
MDA (µmol/mL)	1	6	5.82±1.86	3.76-9.21	<0.001*	1-2:<0.001*
	2	6	10.61±1.65	8.7-13.2		1-3:0.224
	3	6	7.5±1.49	5.2-9.6		2-3:0.015*
PC (nmol/mL)	1	6	463.14±117.09	333.23-664.9	0.008*	1-2:0.006*
	2	6	690.8±97.54	558.57-799.92		1-3:0.109
	3	6	597.38±106.07	403.13-706.81		2-3:0.013*
IL-1Beta (µg/dL)	1	6	0.97±0.08	0.85-1.04	<0.001*	1-2:<0.001*
	2	6	2.77±0.51	1.74-3.1		1-3:0.157
	3	6	1.36±0.29	1.01-1.78		2-3<0.001*
IL-6 (ng/L)	1	6	10.15±2.4	6.32-13.2	0.008*	1-2:0.007*
	2	6	17.34±4.37	10.1-23.2		1-3:0.544
	3	6	12.29±3.33	7.71-17.2		2-3:0.007*
TNF-Alpha (ng/dL)	1	6	43.45±9.02	33.02-53.43	0.002*	1-2:0.002*
	2	6	73.46±16.38	52.31-94.4		1-3:0.163
	3	6	56.94±9.36	46.2-70.8		2-3:0.026*

Abbreviations: SOD: Superoxide Dismutase; GSH-Px: Glutathione Peroxidase; MDA: Malondialdehyde; PC: Protein Carbonyl; IL-1Beta: Interleukin 1 Beta; IL-6: Interleukin-6; TNF-Alpha: Tumor Necrosis Factor Alpha; SD: Standard Deviation. Test: One-Way Analysis of Variance (ANOVA). (Differences between groups were examined with Post-Hoc Tukey's Honestly Significant Difference (HSD) or Tamhane's T2 test). *Statistically significant (p<0.05).

Table 2. Comparison of hemorrhage, edema, vasocongestion, inflammation, and Johnsen scores between rat groups

	Groups	N	Mean±SD	Median (Min-Max)	p-Values	Post-Hoc p-Values
Hemorrhage	1	6	0.28±0.08	0.27 (0.2-0.43)	<0.001*	1-2:<0.001*
	2	6	2.34±0.23	2.34 (2.04-2.61)		1-3:0.155
	3	6	1.22±0.19	1.27 (0.95-1.42)		2-3:0.015*
Edema	1	6	0.33±0.1	0.33 (0.23-0.45)	<0.001*	1-2:<0.001*
	2	6	2.23±0.26	2.19 (1.93-2.63)		1-3:0.154
	3	6	1.02±0.16	1.08 (0.8-1.17)		2-3:0.035*
Vasocongestion	1	6	0.36±0.04	0.36 (0.3-0.42)	<0.001*	1-2:<0.001*
	2	6	2.32±0.18	2.26 (2.16-2.59)		1-3:0.155
	3	6	1.18±0.16	1.12 (1.05-1.46)		2-3:0.015*
Inflammation	1	6	0.31±0.14	0.27 (0.18-0.57)	<0.001*	1-2:<0.001*
	2	6	2.03±0.12	2 (1.88-2.24)		1-3:0.154
	3	6	1.11±0.19	1.05 (0.94-1.48)		2-3:0.034*
Johnsen Score	1	6	9.88±0.04	9.89 (9.81-9.93)	<0.001*	1-2:<0.001*
	2	6	6.33±0.36	6.23 (5.97-6.81)		1-3:0.154
	3	6	8.77±0.44	8.82 (8.14-9.4)		2-3:0.034*

Test: One-Way Analysis of Variance (ANOVA). (Differences between groups were examined with Post-Hoc Tukey's Honestly Significant Difference (HSD) or Tamhane's T2 test). *Statistically significant (p<0.05).

assessment. Post-Hoc Tukey's Honestly Significant Difference (HSD) or Tamhane's T2 test was used for further comparisons. P-values were considered statistically significant if less than 0.05. Calculations were performed using statistical software (IBM SPSS Statistics 22, SPSS Inc., IBM Co., Somers, NY).

A literature review was conducted to determine the number of samples to be included in the study, and the effect size for the reference article was calculated to be 1.2.^[2] Based on the calculated effect size ($\alpha=0.05$; $1-\beta=0.80$), the minimum sample size required was 12. G*Power software, version 3.1.9.7, University of Dusseldorf, Germany, was used for these calculations.^[16]

RESULTS

Biomechanical Findings

In Group 2, MDA and PC values were recorded at 10.61 ± 1.65 and 690.8 ± 97.54 , respectively. These values were significantly decreased in Group 3 ($p=0.015$ and $p=0.013$, respectively). Proinflammatory cytokine levels were also suppressed in Group 3 compared to Group 2 (for IL-1 Beta $p=0.001$, for IL-6 $p=0.007$, for TNF-alpha $p=0.026$, respectively). When antioxidant enzyme levels were analyzed, it was found that both GSH-Px and SOD levels were higher in Group 3 compared to Group 2 ($p=0.025$ and $p=0.005$, respectively) (Table 1).

Histopathological Findings

The histopathological results are detailed in Table 2. Scores

for hemorrhage, edema, vasocongestion, and inflammation in Group 2 were negatively impacted compared to Group 1. In Group 3, edema and vasocongestion scores were recorded at 1.02 ± 0.16 and 1.18 ± 0.16 , respectively. These values were found to be lower than those in Group 2 ($p=0.035$ and $p=0.015$, respectively). There was also a significant decrease in inflammation and hemorrhage scores in Group 3 compared to Group 2 ($p=0.034$ and $p=0.015$, respectively). The Johnsen score in Group 3 was calculated to be 8.77 ± 0.44 , showing significant improvement compared to Group 2 ($p=0.034$) (Fig. 1). No severe histopathological damage was observed in the rats in Group 3.

DISCUSSION

Testicular torsion is a severe and acute urological emergency. Epidemiological studies indicate that testicular torsion affects 1 in 4,000 males under the age of 25 each year. Early recognition and treatment of testicular torsion are closely associated with increased rates of testicular salvage. The success rate of surgical intervention within 4-8 hours after symptom onset is between 90-100%, but this rate drops to about 10% within 24 hours.^[17] Despite successful surgical detorsion, testicular atrophy and dysfunction are observed in approximately 50% of cases, directly related to testicular ischemia-reperfusion injury. Our understanding of testicular ischemia-reperfusion injury remains limited.^[18]

Testicular torsion occurs when the spermatic cord twists

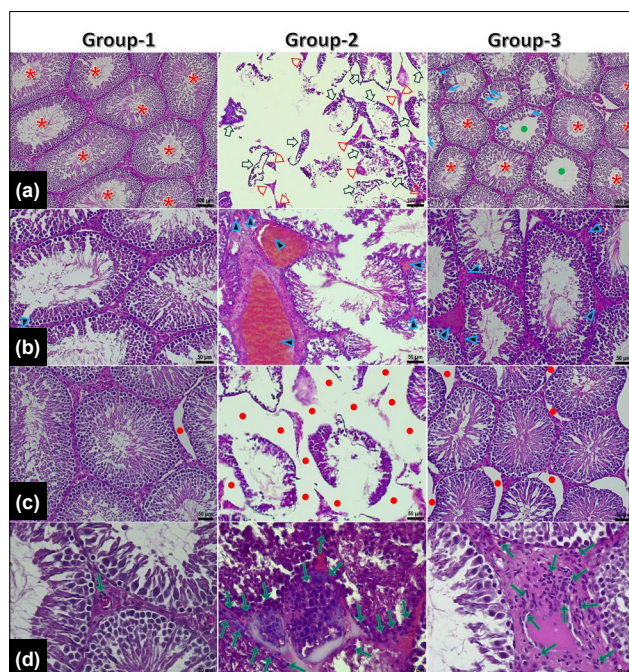


Figure 1. Representative microscopic testicular section images from our study groups.

• The images in row A represent comparisons of the Johnsen score between the groups:

- Normal seminiferous tubules and spermiogenesis in Group 1
- Mostly deformed seminiferous tubules with disrupted integrity and tissue fragments in interstitial areas in Group 2.

– In Group 3, the integrity of seminiferous tubules and interstitial areas is preserved, with mild deformity in the seminiferous tubule epithelium and slight damage with absence of spermatozoa in the lumen of some tubules (red star: normal seminiferous tubules, blue arrow: deformed seminiferous tubule epithelium, green dot: no spermatozoa in the lumen, hollow thick arrow: severely damaged seminiferous tubules, red arrowhead: remnants of interstitial space).

• The images in row B are comparisons of vasocongestion and hemorrhage between the groups:

- Normal stromal areas with normal caliber vascular structures in Group 1.
- Intense vasocongestion and severe hemorrhagic area in Group 2
- Moderate vasocongestion and hemorrhagic areas in Group 3 (arrowheads: hemorrhagic and vasocongestion areas).

• The images in row C are comparisons of edema between the groups.

- In Group 1, edema is minimal to negligible.
- In Group 2, there is marked and diffuse edema.
- In Group 3, edema is mild (red dot: areas of edema).

• The images in row D are comparisons of inflammation between the groups.

- In Group 1, inflammatory cell infiltration is minimal to negligible.
- In Group 2, there are areas of intense inflammatory cell infiltration.
- In Group 3, areas of inflammatory cell infiltration are moderate (green arrow: areas of inflammatory cell infiltration).

(Scale bars are set at 50 μ m for rows A, B, and C, and 20 μ m for row D. Staining method: Hematoxylin and eosin).

around itself, compromising blood flow to the testis. During this period, testicular tissue becomes deprived of high-energy molecules, leading to an accumulation of low-energy

molecules such as adenosine monophosphate, purines, and adenosine. When the spermatic cord is returned to its original position, the testicular tissue is exposed to significant levels of oxygen. Consequently, a series of reactions mediated by xanthine oxidase generates a substantial amount of reactive oxygen radicals. In testicular ischemia-reperfusion injury, the decreased levels of antioxidant enzyme activity and the sudden increase in reactive oxygen radical levels lead to significant oxidative stress in testicular tissue.^[1,2] Testicular tissue is highly susceptible to oxidative stress due to the high levels of polyunsaturated fatty acids in the cell membrane. In this context, numerous studies have extensively observed the impairment of spermatogenesis and the impact on testicular endocrine functions due to testicular ischemia-reperfusion injury.^[1,18]

The study by Kazaz et al. reported a decrease in seminiferous tubule diameter and germinal epithelium thickness as a secondary effect of testicular ischemia-reperfusion injury.^[19] Abdel-Gaber et al. observed a decrease in testicular weight in cases of testicular ischemia-reperfusion injury.^[20] Similarly, a study by Chi et al. reported a decrease in testicular cellularity due to testicular torsion-detorsion.^[21] In our study, significant increases in tissue damage parameters such as hemorrhage, edema, vasocongestion, and inflammation secondary to testicular ischemia-reperfusion injury were documented. Additionally, spermatogenesis is severely affected by pathologies such as DNA damage, inhibition of protein synthesis, and spermatogonial arrest secondary to testicular ischemia-reperfusion injury.^[18] Even in successful treatment regimens, approximately one-fourth of patients may experience infertility.^[1] Koksall et al. reported an increase in the rate of abnormal sperm due to testicular ischemia-reperfusion injury.^[22] Similarly, Ikebuaso et al. observed a decrease in sperm count and sperm motility due to testicular ischemia-reperfusion injury.^[23] In our study, a significant decrease in the Johnsen score was observed secondary to testicular ischemia-reperfusion injury.

Lidocaine ($C_{14}H_{22}N_2O$) was first introduced by Nils Lofgren in 1942. The use of local anesthesia for analgesic purposes became quite widespread in the mid-19th century, alongside the use of antiarrhythmic drugs. Today, both acute and chronic pain conditions are significantly alleviated by the evidence-based antinociceptive and antihyperalgesic effects of lidocaine.^[4,24] Recent studies have also focused on lidocaine as a pharmacological agent highly effective in suppressing oxidative stress. The modulation of the inflammatory response, inhibition of Na^+/Ca^{++} exchange, and scavenging of reactive oxygen species (ROS) are shown as the primary cytoprotective mechanisms of this local anesthetic agent.^[25,26] The anti-inflammatory properties of lidocaine have been documented in numerous experimental and clinical studies. It suppresses macrophage activation and blocks the production of inflammatory mediators such as IL-4, IL-6, and TNF-alpha, while also inhibiting the release of prostaglandins, thromboxane, and histamine.^[24,27] Lidocaine also acts as a Na^+/Ca^{++} channel

blocker. In this context, inhibiting calcium, which serves as a cofactor in the conversion of xanthine dehydrogenase to xanthine oxidase, results in a decrease in the formation of superoxide radicals.^[25] Additionally, lidocaine exhibits protective effects on endothelial damage caused by both superoxide and hydroxyl radicals by scavenging reactive oxygen species.^[5,25]

Jiang et al. found that lidocaine attenuates hippocampal neuronal apoptosis, regulates inflammation, and mitigates oxidative stress, thereby improving cognitive function in rats in a cerebral ischemia-reperfusion injury model. In the same study, it was observed that MDA levels decreased following lidocaine treatment, while increases in the activities of SOD and GSH-Px were noted.^[6] Similarly, Deng et al. reported that lidocaine administration resulted in higher glutathione levels in rats with a renal ischemia-reperfusion model, demonstrating renoprotective activity due to this antioxidant property.^[7] In our study, a significant increase in antioxidant enzyme levels and a regression in testicular histopathological damage markers were observed in lidocaine-treated rats. Tasi et al. documented that lidocaine exhibited moderate neuroprotective activity in a retinal ischemia-reperfusion model.^[8] Another study reported that lidocaine is a molecule that may play a potential role in modulating platelet activation, the inflammatory response, and sepsis.^[26] In the study conducted by Eskitascioglu et al., it was documented that lidocaine exhibited a membrane-stabilizing effect and protected flap tissue from ischemia-reperfusion injury by inhibiting the increase in MDA levels.^[10] In a similar study, Cao et al. reported that lidocaine treatment increased SOD activity, eliminated free oxygen radicals, suppressed inflammatory reactions, and thereby improved flap survival.^[28] Leduc et al. observed that lidocaine administered via the sciatic nerve significantly reduced lipid peroxidation in an inflammatory rat model.^[29] In our study, it was determined that inflammation was suppressed and a decrease in the levels of MDA and PC was observed following lidocaine administration in a similar manner.

CONCLUSION

In our experimental study, it was documented that lidocaine exhibited protective efficacy against testicular ischemia-reperfusion injury, characterized by higher antioxidant enzyme activity, suppressed inflammatory response, and lower levels of lipid peroxidation and protein oxidation. We believe that these findings may serve as the basis for further clinical and experimental studies to elucidate the therapeutic role of lidocaine, a local anesthetic agent, in testicular torsion/detorsion.

Limitations of This Study

The limitations of our study include examining the effect of lidocaine on testicular tissue samples using only one technique. Additionally, the side effect profile of lidocaine on the reproductive system was not documented, and the long-term effects of this local anesthetic agent on testicular tissue could not be evaluated.

Ethics Committee Approval: This study was approved by the Tokat Gaziosmanpaşa University Faculty of Medicine Ethics Committee (Date: 19.01.2024, Decision No: 5187983-08).

Peer-review: Externally peer-reviewed.

Authorship Contributions: Concept: Y.K., M.G.B., H.T., T.K., S.K., F.F. Design: V.K., K.Y., F.G., S.K., V.U., M.G.B. Supervision: V.K., H.T., T.K., S.K., F.F., K.Y. Materials: V.K., F.F., K.Y., F.G., V.U., H.T. Data Collection and/or Processing: V.K., M.G.B., T.K., S.K., K.Y., F.F. Analysis and/or Interpretation: V.K., K.Y., F.F., M.G.B., V.U., T.K.; Literature Search: V.K., F.F., F.G., H.T., K.Y.; Writing: V.K., H.T., M.G.B., F.F., K.Y.; Critical Reviews: V.K., M.G.B., S.K., T.K., H.T., K.Y., F.F., V.U.

Conflict of Interest: None declared.

Financial Disclosure: The author declared that this study has received no financial support.

REFERENCES

- Kölükçü E, Atılğan D, Uluocak N, Deresoy FA, Katar M, Unsal V. Milrinone ameliorates ischaemia-reperfusion injury in experimental testicular torsion/detorsion rat model. *Andrologia* 2021;53:14128. [\[CrossRef\]](#)
- Kölükçü E, Firat F, Deresoy FA, Katar M, Atılğan D. The effects of pirlfenidone on ischaemia-reperfusion injury in testicular torsion-induced rat model. *Andrologia* 2021;53:13922. [\[CrossRef\]](#)
- Özçeker D, Tamay Z, Güler N. Local anaesthetic neurotoxicity mimicking anaphylaxis. *J Curr Pediatr* 2015;13:151–4. [\[CrossRef\]](#)
- Foong KW, Chaw SH, Lo YL, Loh PS. Population pharmacokinetics of intravenous lidocaine in adults: a systematic review. *Clinical Pharmacokinetics* 2024;63:623–43. [\[CrossRef\]](#)
- Foo I, Macfarlane AJR, Srivastava D, Bhaskar A, Barker H, Knaggs R, et al. *Anaesthesia* 2021;76:238–50. [\[CrossRef\]](#)
- Jiang R, Liao J, Yang MC, Deng J, Hu YX, Li P, et al. Lidocaine mediates the progression of cerebral ischemia/reperfusion injury in rats via inhibiting the activation of NF-κB p65 and p38 MAPK. *Ann Transl Med* 2020;8:548. [\[CrossRef\]](#)
- Deng Y, Li RW, Yang YL, Weiss S, Smith PN. Pharmacological prevention of renal ischemia-reperfusion injury in a rat model. *ANZ J Surg* 2022;92:518–25. [\[CrossRef\]](#)
- Tasi WC, Petersen-Jones SM, Huang PY, Lin CT. The neuroprotective effects of lidocaine and methylprednisolone in a rat model of retinal ischemia-reperfusion injury. *J Vet Med Sci* 2012;74:307–13. [\[CrossRef\]](#)
- Meštrović J, Drmić-Hofman I, Pogorelić Z, Vilović K, Šupe-Domić D, Perišin AŠ, et al. Beneficial effect of nifedipine on testicular torsion-detorsion injury in rats. *Urology* 2014;84:1194–8. [\[CrossRef\]](#)
- Eskitascioglu T, Karaci S, Canoz O, Kilic E, Gunay GK. The impact of lidocaine on flap survival following reperfusion injury. *J Surg Res* 2011;167:323–8. [\[CrossRef\]](#)
- Johnsen S. G. Testicular biopsy score count--a method for registration of spermatogenesis in human testes: normal values and results in 335 hypogonadal males. *Hormones* 1970;1:2–25. [\[CrossRef\]](#)
- Sun, Y, Oberley, LW, Li, Y. A simple method for clinical assay of superoxide dismutase. *Clin Chem* 1988;34:497–500. [\[CrossRef\]](#)
- Paglia, DE, Valentine, WN. Studies on the quantitative and qualitative characterisation of erythrocyte glutathione peroxidase. *J Lab Clin Med* 1967;70:158–69.
- Esterbauer, H, Cheeseman, KH. Determination of aldehydic lipid peroxidation products: malonaldehyde and 4-hydroxynonenal. *Methods Enzymol* 1990;186:407–21. [\[CrossRef\]](#)
- Levine RL, Garland D, Oliver CN, Amici A, Climent I, Lenz AG, et

- al. Determination of carbonyl content in oxidatively modified proteins. *Methods Enzymol* 1990;186:464–78. [CrossRef]
16. Faul F, Erdfelder E, Lang AG, Buchner A. G*Power 3: a flexible statistical power analysis program for the social, behavioral, and biomedical sciences. *Behav Res Methods* 2007;39:175–91. [CrossRef]
 17. Alzahrani MA, Alasmari MM, Altokhais MI, Alkeraithe FW, Alghamdi TA, Aldaham AS, et al. Is there a relationship between waking up from sleep and the onset of testicular torsion? *Res Rep Urol* 2023;15:91–8.
 18. Li ZM. Role of antioxidants in preventing testicular ischemia-reperfusion injury: a narrative review. *Eur Rev Med Pharmacol Sci* 2022;26:9126–43.
 19. Kazaz IO, Mentese A, Demir S, Kerimoglu G, Colak F, Bodur A, et al. Berberine inhibits the ischemia-reperfusion induced testicular injury through decreasing oxidative stress. *Am J Emerg Med* 2020;38:33–7.
 20. Abdel-Gaber SA, Mohammed RK, Refaie MMM. Mechanism mediating the protective effect of diacerein in ischemia-reperfusion-induced testicular injury in rats. *Life Sci* 2018;209:57–62. [CrossRef]
 21. Chi KK, Zhang WH, Wang GC, Chen Z, He W, Wang SG, et al. Comparison of intraperitoneal and intraepididymal quercetin for the prevention of testicular torsion/detorsion-induced injury. *Urology* 2017;99:106–11. [CrossRef]
 22. Koksall M, Oğuz E, Baba F, Eren MA, Ciftci H, Demir ME, et al. Effects of melatonin on testis histology, oxidative stress and spermatogenesis after experimental testis ischemia-reperfusion in rats. *Eur Rev Med Pharmacol Sci* 2012;16:582–8.
 23. Ikebuaso AD, Yama OE, Duru FIO, Oyeadejo SA. Experimental testicular torsion in a rat model: effects of treatment with pausynstalia macrocera on testis functions. *J Reprod Infertil* 2012;13:218–24.
 24. Hermanns H, Hollmann MW, Stevens MF, Lirk P, Brandenburger T, Piegeler T, et al. Molecular mechanisms of action of systemic lidocaine in acute and chronic pain: a narrative review. *Br J Anaesth* 2019;123:335–49. [CrossRef]
 25. Benjamin H, Cassutto DVM, Roger W, Gfeller DVM, DACVECC. Use of intravenous lidocaine to prevent reperfusion injury and subsequent multiple organ dysfunction syndrome. *J Vet Emer Crit Care* 2003;13:137–48. [CrossRef]
 26. Huang GS, Lin TC, Wang JY, Ku CH, Ho ST, Li CY. Lidocaine priming reduces ADP-induced P-selectin expression and platelet-leukocyte aggregation. *Acta Anaesthesiol Taiwan* 2009;47:56–61. [CrossRef]
 27. Boswell MR, Moman RN, Burtoft M, Gerdes H, Martinez J, Gerber DJ, et al. Lidocaine for postoperative pain after cardiac surgery: a systematic review. *J Cardiothorac Surg* 2021;16:157. [CrossRef]
 28. Cao B, Wang L, Lin D, Cai L, Gao W. Effects of lidocaine on random skin flap survival in rats. *Dermatol Surg* 2015;41:53–8. [CrossRef]
 29. Leduc C, Gentili ME, Estèbe JP, Corre PL, Moulinoux JP, Ecoffey C. The effect of local anesthetics and amitriptyline on peroxidation in vivo in an inflammatory rat model: preliminary reports. *Anesth Analg* 2002;95:992–6. [CrossRef]

DENEYSSEL ÇALIŞMA - ÖZ

Bir deneysel çalışma: Testis torsiyonunda lidokainin iskemi-reperfüzyon hasarına etkisi var mıdır?

Vildan Kölükçü,¹ Mehtap Gürler Balta,¹ Hakan Tapar,¹ Tugba Karaman,¹ Serkan Karaman,¹ Velid Unsal,² Fikret Gevrek,³ Kenan Yalçın,⁴ Fatih Frat⁴

¹Tokat Gaziosmanpaşa Üniversitesi Tıp Fakültesi, Anestezi ve Reanimasyon Anabilim Dalı, Tokat, Türkiye

²Mardin Artuklu Üniversitesi, Sağlık Bilimleri Fakültesi ve Merkezi Araştırma Laboratuvarı, Mardin, Türkiye

³Tokat Gaziosmanpaşa Üniversitesi Tıp Fakültesi, Histoloji ve Embriyoloji Anabilim Dalı, Tokat, Türkiye

⁴Tokat Gaziosmanpaşa Üniversitesi Tıp Fakültesi, Üroloji Anabilim Dalı, Tokat, Türkiye

AMAÇ: Bu deneysel çalışmada sıçanlarda testis torsiyonu/detorsiyonuna bağlı iskemi-reperfüzyon hasarında lidokainin olası koruyucu etkilerinin değerlendirilmesi amaçlanmıştır.

GEREÇ VE YÖNTEM: Toplam 18 erkek rat 3 gruba randomize edildi. Grup-1 kontrol grubu olarak belirlendi. Grup-2'de torsiyonu/detorsiyon modeli oluşturularak testis iskemi- reperfüzyon hasarının değerlendirildiği grup olarak tanımlandı. Grup 3 ise tedavi grubu idi. Bu grupta Grup 2 ile benzer iskemi-reperfüzyon modeli oluşturuldu ve ek olarak reperfüzyondan 5 dakika önce 15 mg/kg lidokain intraperitoneal olarak uygulandı. Kan biyokimyasal analizi ve testis histopatolojik değerlendirilmesi yapıldı.

BULGULAR: Kan biyokimyasal analizlerinde MDA ve PC değeri Grup 2'de diğer gruplara göre ciddi düzeyde artmış olarak belirlendi (sırasıyla $p<0.001$ ve $p=0.008$). Grup 3'de IL-1, IL-6 ve TNF-alfa olmak üzere proinflatmatuvur sitokin düzeyinde Grup 2'ye göre baskılanmış olarak belirlendi (sırasıyla; $p<0.001$, $p=0.007$ ve $p=0.026$). Antioksidan enzim düzeyinde ise hem SOD hemden GSH-Px aktiviteleri Grup 3'de Grup 2'ye göre artmış olarak kayıt edildi ($p=0.005$ ve $p=0.025$). Histopatolojik değerlendirmelerimizde Grup 3'de kanama, ödem, vazokonjesyon ve inflamasyon olmak üzere tüm testiküler hasar skorlarında Grup 2'ye göre dramatik olarak iyileşme gözlemlendi (sırasıyla; $p=0.015$, $p=0.035$, $p=0.015$ ve $p=0.034$). Benzer şekilde Grup 3'te Johnsen skoru üzerinde Grup 2'ye göre olumlu etki tespit edildi ($p=0.034$).

SONUÇ: Lidokain testis iskemi-reperfüzyon hasarının etkilerini hafifletmede etkin bir lokal anestetik ajandır.

Anahtar sözcükler: Anestezi; lidokain; iskemi-reperfüzyon; testis.

Ulus Travma Acil Cerrahi Derg 2024;30(10):708-714 DOI: 10.14744/tjtes.2024.54534