

The Effects of Superficial Musculoaponeurotic System Flap on the Development of Frey's Syndrome and Cosmetic Outcomes After Superficial Parotidectomy

Ömer Bayır¹, Elif Kaya Çelik¹, Güleser Saylam¹, Emel Çadallı Tatar¹, Cem Saka¹, Muharrem Dağlı², Ali Özdek¹, Mehmet Hakan Korkmaz³

¹Department of Otolaryngology, Head and Neck Surgery, Dışkapı Yıldırım Beyazıt Training and Research Hospital, Ankara, Turkey

²Department of Otolaryngology, Head and Neck Surgery, Abant İzzet Baysal University School of Medicine, Bolu, Turkey

³Department of Otolaryngology, Head and Neck Surgery, Yıldırım Beyazıt University School of Medicine, Ankara, Turkey

Original Investigation

Abstract

Objective: To investigate the outcomes of superficial musculoaponeurotic system (SMAS) flap and classic techniques in superficial parotidectomy in terms of Frey's syndrome (FS) and cosmetic satisfaction.

Methods: In this study, a retrospective chart review of patients that underwent superficial parotidectomy was performed. These patients were divided into two subgroups: group 1 included patients in which the SMAS flap was harvested and group 2 comprised the remaining patients on whom classic superficial parotidectomy was performed. All the patients were evaluated clinically and with Minor's starch-iodine test for FS. For the evaluation of the cosmetic results, the patient's satisfaction was queried according to the incision scar and surgical field skin retraction/facial symmetry. Both groups were compared in terms of complications and numbness of surgical area.

Results: Fifty-five patients (31 male and 24 female) with a mean age of 50.19 years were included in the study. Thirty-two patients were in group 1 and 23 in

group 2. Thirteen patients (23.7%) described as having FS and six of them were in group 1, while seven were in group 2. Minor's starch-iodine test was positive in nine patients in group 1 (28.1%) and six patients in group 2 (26.1%) ($p=1.000$). With regard to cosmetic satisfaction, eight patients (25%) stated mild discomfort from the incision scar and two patients (6.3%) stated cosmetic dissatisfaction for facial asymmetry in group 1. In group 2 for the same factors the number of patients were 11 (47.8%) and 2 two (8.7%), respectively ($p=0.027$). There were no statistically significant differences in means of complication and numbness ($p>0.05$).

Conclusion: According to our study results, there was no superiority between both the groups in terms of FS and incision scar satisfaction. We determined that there was a significant benefit of SMAS flap application in the prevention of volume loss and surgical area retraction.

Keywords: Parotid neoplasms, surgery, Frey's syndrome, cosmetic technique, SMAS

Introduction

Parotid tumors constitute 2% of all head and neck tumors: 80% of these are benign and mostly located in the superficial lobe (1-3). Therefore, the removal of superficial parotid tissue is the standard treatment. The well-known complications of this surgery are facial nerve paresis or paralysis, salivary fistula, infection, skin numbness, cosmetic problems (incision scar dissatisfaction, keloid formation, or skin retraction due to significant tissue removal) and Frey's syndrome (FS) (4, 5). FS is also defined as auriculotemporal syndrome or gustatory sweating, and it is characterized by sweating, erythema, and warmth on the preauricular-temporal region during eating. The first case series of FS with today's definition was reported by Baillarger et al in 1853 (6, 7).

The incidence of FS was reported as 4-97% in several studies (8-12). There are objective and subjective evaluation methods for the diagnosis of FS. Subjective diagnoses are based on the patients' symptoms, but most of these cases are not clinically overt. Objective diagnoses are made by using some tests, mostly using the Minor's starch-iodine test (9). In patients with a positive diagnosis of FS, different medical and surgical techniques can be used for treatment. Botulinum A injection, using systemic anti-cholinergic agents, sternocleidomastoid muscle (SCM) rotation, fascia lata transplantation, and dermal-fat graft applications are some examples of these treatment methods (13-17). However, none of these techniques yield a completely successful remedy. Superficial muscu-



This study was presented as an oral presentation at the 37th Turkish National Congress of Otorhinolaryngology-Head and Neck Surgery 28 October-1 November 2015, Antalya, Turkey.

Address for Correspondence:

Ömer Bayır

E-mail: bayiromer@hotmail.com

Received Date: 04.11.2016

Accepted Date: 29.11.2016

© Copyright 2016 by Official Journal of the Turkish Society of Otorhinolaryngology and Head and Neck Surgery Available online at www.turkarchotorhinolaryngol.org

DOI: 10.5152/tao.2016.1987

loaponeurotic system (SMAS) flap is the most widely performed technique for the prevention of both FS and poor cosmetic outcomes.

The aim of this study was to investigate the effect of SMAS flap on FS development and cosmetic satisfaction in patients who underwent superficial parotidectomy.

Methods

The study was retrospectively designed, and it has been approved by the local ethical committee of our hospital (25/12-20.08.2015). Patients who underwent superficial parotidectomy operation for benign parotid tumors between January 2006 and January 2015 in our clinic were evaluated. Patients who underwent a surgical procedure other than superficial parotidectomy (enucleation or total parotidectomy), had a previous history of parotid surgery, or underwent radiation treatment to the head and neck region were excluded from the study. The patients were divided into two groups according to the technique of superficial parotidectomy used: group 1 included patients who were operated upon with a separately elevated skin and SMAS flap (Figure 1). Group 2 included patients who were operated upon with a classical skin flap without sparing the SMAS. These two different techniques have been performed in our clinic for years. Patients who were operated at least 6 months ago and came for the control (after invitation by phone call) were included in our study, and written informed consents were obtained from them as well as their demographic data.

In the evaluation of patients, the presence of sweating, hyperemia, warmth, and discomfort during eating on the parotid area were queried for the FS diagnosis. Following the questions, the patient’s hyperhidrosis severity scale was measured in the form of “Yes” or “No” (18). The cosmetic results were evaluated with a questionnaire of satisfaction with respect to the wound scar and skin retraction on the surgical region (asymmetry) (Table 1). This questionnaire was modified according to the studies by Barbera et al. (19) and Amin et al (20). After the evaluation of the questionnaires, Minor’s starch-iodine test was performed on all the patients. First, bilateral preauricular, postauricular, temporal, and ear lobule regions of the patients were cleaned, dried, and then a solution including 10% polyvinyl pyrrolidone iodine complex was topically applied. After the drying of this agent, cornstarch was applied as the second layer. Patients were asked to drink a small glass of lemon saltwater mixture for 20 min. The photographs of the patients before ingestion, and at the 1st, 10th, and 20th minute after ingestion were obtained. These images were evaluated, and a blue-black discoloration was defined as a positive outcome (Figure 2). The results were interpreted as negative if the discoloration was not present; mild, if the discoloration was smaller than 2 cm²; moderate, if the discoloration was between 2 and 4 cm²; and severe, if the discoloration was larger than 4 cm².

Statistical analysis

For the statistical analysis, IBM Statistical Package for the Social Sciences for Windows Version 21.0 (IBM Corp.; Armonk, NY, USA) program was used. Numerical data are summarized as mean ± standard deviation or median [min–max], while the categorical data are represented using numbers and percentages. The variances of the numerical data between 2 independent samples were investigated with independent samples t-test when the parametric test presumption was provided. When this presumption could not be provided, the Mann–Whitney U-test was used. The differences between both the groups with regard to categorical variables were investigated with the chi-square test or Fisher’s exact test. The significance level was regarded as p<0.05.

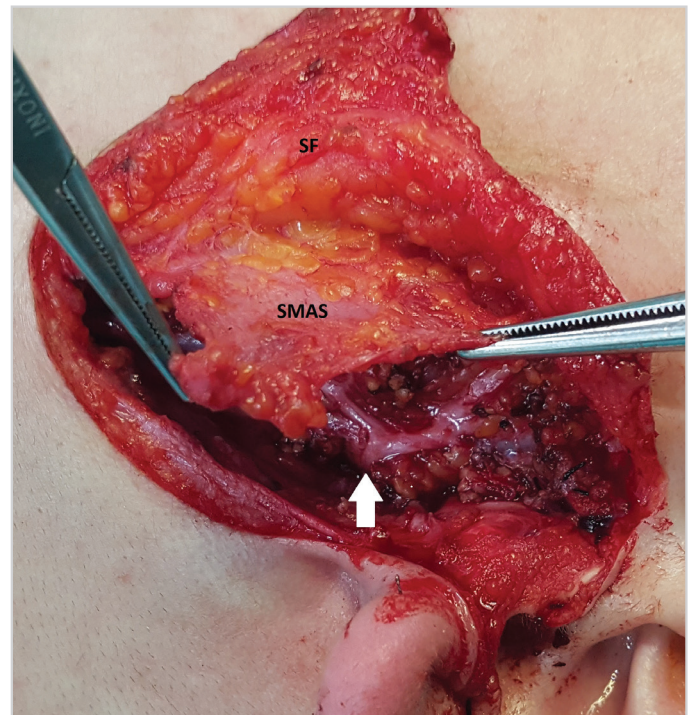


Figure 1. Sample of superficial parotidectomy with the SMAS flap technique. SMAS and the skin were elevated separately. SF: skin; SMAS: superficial musculoaponeurotic system flap; white arrow: facial nerve

Table 1. Questionnaire for the subjective evaluation of cosmetic results including wound scar and asymmetric retraction of the surgical area

Cosmetic evaluation	
1- How does the wound scar on operation area make you feel?	
I am not any discomfortable	1
I am a little discomfortable	2
I am discomfortable	3
I am very discomfortable	4
2- Does asymmetric appearance (retraction) between the operation side and the other side disturb you?	
Asymmetry (retraction) is not present	1
I am a little discomfortable	2
I am discomfortable	3
I am very discomfortable	4

Results

Totally, 55 patients (31 male and 24 female) with a mean age of 50.19 years were included in the study. Thirty-two patients were in group 1 and 23 in group 2. In 28 (50.9%) and 27 (49.1%) patients, right and left superficial parotidectomy operations were performed, respectively. No significant difference was observed between the groups in terms of mean age ($p=0.109$) and gender distribution ($p=1.000$). The histopathological examinations of the operative specimens were reported as pleomorphic adenoma (n:25; 45.4%), Warthin tumor (n:20; 36.3%), chronic inflammation (n:5; 9%), lipoma (n:2; 3.6%), basal cell adenoma (n:2; 3.6%), and epidermal cyst (n:1; 1.8%). The mean follow-up period was 18 months in group 1 and 36 months in group 2. In subjective evaluations, 13 (23.7%) patients defined FS symptoms in the operation region. Six (18.8%) of these patients were in group 1, while seven were in group 2 (30.4%). With regard to the results of the objective evaluations with Minor's starch-iodine test, 15 (27.3%) patients were diagnosed as showing FS symptoms. Nine (28.1%) of these patients were in group 1, while six (26.1%) were in group 2 ($p=1.000$). When the severity of the Minor's test was evaluated, group 1 had five (15.6%) mild, three (9.4%) moderate, and one (3.1%) severe FS cases, and group 2 had four (17.4%) mild and two (8.7%) severe FS cases. When the wound scar satisfaction was queried, group 1 had 21 (65.6%) patients who were not uncomfortable any more, while nine (28.2%) were a little uncomfortable, one (3.1%) was uncomfortable, and one (3.1%) was highly uncomfortable. In group 2, 20 (86.9%) patients were not uncomfortable any more, while three (13.1%) were a little uncomfortable ($p=0.216$). In the evaluation of retraction, in group 1, 22 (68.7%) patients reported that they did not see any asymmetry, while eight (25%) patients reported a slight disturbance and two (6.3%) patients reported disturbance. In group 2, 10 (43.5%) patients reported no asymmetry anymore, while 11 (47.8%)

patients reported a little discomfort and two (8.7%) patients reported high levels of discomfort ($p=0.027$). In group 1, in the early postoperative period, six (18.75%) patients had parotid fistula, two (6.25%) patients had hematoma, and two (6.25%) patients had transient marginal paralysis. In group 2, one (4.34%) patient had parotid fistula, one (4.34%) patient had hematoma, and six (26%) patients had transient marginal paralysis. When we compared the presence of complications between the groups, there were no statistically significant differences ($p=0.948$). Fourteen (43.8%) patients in group 1 and 11 (56.5%) patients in group 2 complained of numbness in the surgical area, but there was no statistically significant difference between the groups ($p=0.509$). The results are summarized in (Table 2).

Discussion

Frey's syndrome is characterized with symptoms such as sweating, erythema, and warmth during eating on the parotidectomy area (1, 2-9). Since FS develops due to the aberrant re-innervation between the residual deep parotid tissue and skin sweat glands, the avoidance of the attachment of these two structures is the main aim in the prevention of FS (21). The pathophysiology of FS was first defined as autonomic re-innervation between the skin and parotid gland by Lucja Frey in the early twentieth century (22, 23). In fact, it is thought that FS is the result of the cross-innervation between post-ganglionic secretomotor parasympathetic nerve fibers of the parotid gland and post-ganglionic sympathetic system branches of the skin's sweat glands (8). FS may develop six weeks after operation at the earliest or, more commonly, months later, but a delayed case (14 years after the operation) has also been reported in the literature (8, 9).

Factors known to be associated with FS development are variable and in some studies, the risk factors have been studied. Guntinas-Lichius et al. (24) retrospectively investigated

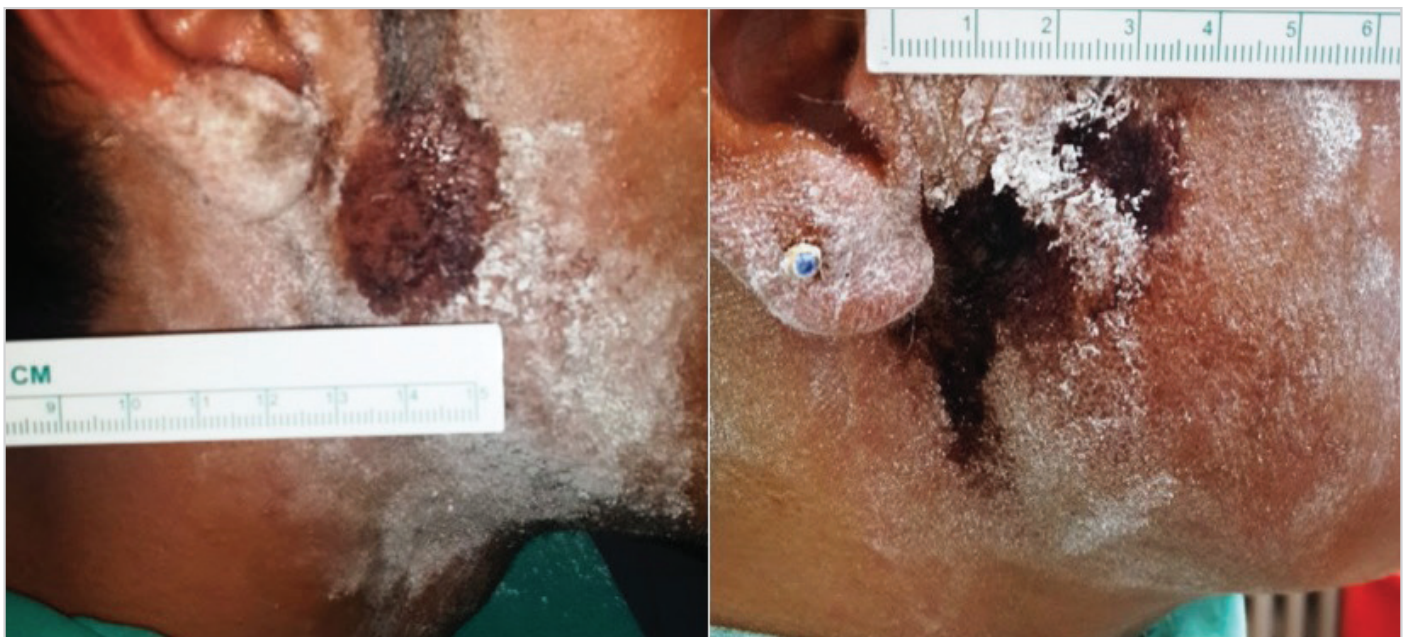

Figure 2. Samples of patients with FS 20 min after sialogogue administration, which shows colored areas and represent a positive Minor's test

Table 2. Demographical data, Minors' starch-iodine test results, and cosmetic evaluations of patients according to the groups

		Group 1 (SMAS flap) (n=32)	Group 2 (Classic technique) (n=23)	p
Age (years)		47.5±14.1	53.7±14.2	0.109
Sex (M/F. n. %)		18/14 (56.3%/43.7%)	13/10 (56.5%/43.5%)	1.000
Follow-up (month)		18 [6–66]	36 [6–108]	0.029
Side (Right/Left. n. %)		15/17 (46.9%/53.1%)	13/10 (56.5%/43.5%)	0.665
Pathology (n. %)	Basal cell adenoma	1 (3.1%)	1 (4.3%)	
	Epidermal cyst	1 (3.1%)	-	
	Chronic inflammation	2 (6.2%)	3 (13%)	
	Lipoma	1 (3.1%)	1 (4.3%)	
	Pleomorphic adenoma	14 (43.8%)	11 (47.8%)	
	Whartin tumor	13 (40.6%)	7 (30.4%)	
Symptom of FS		6 (18.8%)	7 (30.4%)	0.494
Severity of FS symptoms (Hyperhidrosis severity scale)	1	5 (83.3%)	5 (71.4%)	
	2	1 (16.7%)	1 (14.3%)	
	3	-	-	
	4	-	1 (14.3%)	
Minors'iodine-starch test	Negative	23 (71.9%)	17 (73.9%)	
	Mild	5 (15.6%)	4 (17.4%)	
	Moderate	3 (9.4%)	-	
	Severe	1 (3.1%)	2 (8.7%)	
Positive Minors'iodine-starch test		9 (28.1%)	6 (26.1%)	1.000
Incision scar	1	21 (65.6%)	20 (86.9%)	0.216
	2	9 (28.1%)	3 (13.1%)	
	3	1 (3.1%)	-	
	4	1 (3.1%)	-	
Retraction of surgical area	1	22 (68.7%)	10 (43.5%)	0.027
	2	8 (25%)	11 (47.8%)	
	3	2 (6.3%)	-	
	4	-	2 (8.7%)	
Presence of complication		10 (31.25%)	8 (34.7%)	0.948
Numbness of surgical area		14 (43.8%)	13 (56.5%)	0.509

SMAS: superficial musculoaponeurotic system; F: female; M: male; FS: Frey's syndrome

a large case series to define the risk factors of facial paralysis and FS development; they reported severe FS in 25 (4%) patients, but could not determine a significant risk factor for FS development. In a study by Casler and Conley (25), surgical technique, tumor dimensions, histopathological type, skin thickness, age, and gender were found to be unrelated. Rustemeyer et al. (9) reported that FS development was independent of gender or age in 372 patients after parotidectomy. The authors reported a 24% rate of clinical FS in the flapped group, and 21% rate of clinical FS in the non-flapped group among patients with a follow-up of more than

37 months. Their study included patients who underwent surgery in a wide range of techniques (93.4% conservative, 6.4% radical, and 0.2% superficial parotidectomy). Since the FS rates increase in a linear proportion with the extension of surgery, in those non-homogenous groups, a comparison of rates may yield improper results. Therefore, we chose a group with a homogenous disease and surgical procedure in our study.

Different medical and surgical methods have been suggested in the literature for the prevention and treatment of FS;

therefore, various flap techniques and implants have been defined. In many different studies, diverse results have been reported. Although some authors (14, 26-29) have reported that protective methods are useful in the prevention of FS development, some (7, 24, 30, 31) authors have stated that these methods are useless. The main reasons for dissimilar results in studies may be attributed to the non-homogeneity of the groups, insufficient patient numbers and follow-up periods, and differences in techniques and parameters involving FS evaluations.

One of the most commonly reported methods in FS prevention in the literature is using the SCM flap. The SCM flap may be used as a composite or muscle flap in some defects. High levels of blood supply to the SCM muscle facilitate the preparation of the SCM muscle flap with both superior and inferior pedicles (32). In parotidectomy, SCM muscle flap was first used by Kornblut et al (31). In their study, 35 patients who had parotidectomy with the SCM muscle flap were compared with the same number of patients who had parotidectomy without any flaps. In the flapped group, subjective FS was reported in 23% while this ratio was 20% in the un-flapped group; on the other hand, positivity with Minor's starch-iodine test was 94% and 71%, respectively. The authors concluded that the SCM muscle flap did not prevent FS development.

Another method suggested for the prevention of FS is the SMAS flap. This flap is prepared from the fascia of the preauricular region. SMAS is separated from the subcutaneous fat tissue by 2-layered fibrous septa and continues to the neck as platysma (28). Its thickness and muscle content may show variability. Santos et al. (22) evaluated 14 patients who had superficial parotidectomy and followed-up them for at least 6 weeks; the authors reported that the clinical FS ratio was 21% and the ratio of positivity with Minor's starch-iodine test was 21%; consequently, the authors described a correlation between the clinical findings and the test. Allison and Rappaport (33) stated that the SMAS interposition flap is an effective method in the correction of the appearance of parotidectomy patients and the prevention of FS development. Bonanno and Casson (27) reported that they did not determine any clinical FS case in their series of 55 patients with SMAS flap. In the study of Yu and Hamilton (28), it was reported that after parotidectomy with rhytidectomy incision and the preservation of SMAS, satisfactory cosmetic results were obtained and FS rates were decreased. To diminish the postoperative FS development and cosmetic problems, using some implantations and injections (lyophilized dura, adipose tissue, polytetrafluoroethylene, botulinum toxin, etc.) as well as the temporoparietal fascia flap are reported in the literature (13). In our study, we did not determine a statistically significant effect of the SMAS flap in the prevention of FS development. With both subjective evaluation and Minor's test, no difference was observed between the SMAS flap and the patients on whom the classic technique was employed ($p>0.05$). Although the difference was not statistically sig-

nificant, patients with subjective FS were more common (30.4%) in the classic technique group with a more severe disease; similarly, the mean color change area was larger in Minor's starch-iodine test in this group. We had a very homogenous group of patients and surgeries in our study. Furthermore, we had a sufficient length of median follow-up to reach a conclusion, namely, 18 months in the SMAS group and 36 months in the classic technique group. Therefore, we can comment that there is no additional benefit of the SMAS flap over the classic technique to avoid FS.

The use of the SMAS flap elevation and suturing was reviewed systematically by Dulguerov et al. (34) and they stated that it is associated with a decreased incidence of FS. Zhao et al. (35) evaluated the FS and cosmetic results of sub-SMAS flap and SCM flap reconstructions in their study and reported that sub-SMAS flap prevents FS development and SCM muscle flap corrects the cosmetic results. On the other hand, in the study of Taylor et al. (30) in which both subjective and objective FS results were evaluated, classic and sub-SMAS flap techniques were reported not to have any advantage over each other with regard to FS incidence, development time, and severity.

In our study, along with the effects on FS incidence, the relation of SMAS flap to incision line, and retraction deformity were also evaluated. We employed a 2-questioned mini-questionnaire to the patients asking about the incision scar and retraction in the surgical area (asymmetry on the face) in order to evaluate cosmetic satisfaction. We determined that there was a significant benefit of SMAS flap application in the prevention of volume loss and surgical area retraction ($p<0.05$). However, there was no statistically significant difference between the groups regarding the incision scar satisfaction ($p>0.05$). Therefore, our patients were found to be more satisfied with the appearance of the surgical area when SMAS was used.

Preserving nervus auricularis magnus during the operation was suggested to prevent the sensorial loss in the auricular lobule and surgical region in the study by Zhao et al. (35). However, in our study, although in patients operated with the classic technique, higher rates of surgical region numbness was observed, the difference between the groups was not statistically significant. In the study by Zhao et al. (35) the most common complication was transient facial paralysis, but there was no statistically significant difference between the groups. Similarly, in our study, there was no statistically significant difference between the groups in terms of complications.

Conclusion

In conclusion, regarding objective FS development rates, we did not determine any superiority by using the SMAS flap. We can achieve better cosmetic appearance in terms of retraction in surgical area by using SMAS in superficial parotidectomy. However, further studies are warranted with larger patient populations and longer follow-up periods.

Ethics Committee Approval: Ethics committee approval was received for this study from Dışkapı Yıldırım Beyazıt Training and Research Hospital Ethical Committee of our hospital.

Informed Consent: Written informed consent was obtained from patients who participated in this study.

Peer-review: Externally peer-reviewed.

Author contributions: Concept - Ö.B., E.K.Ç., G.S., E.Ç.T., C.S., M.D., A.Ö., M.H.K.; Design - Ö.B., E.K.Ç., G.S.; Supervision - E.Ç.T., C.S., M.D., A.Ö., M.H.K.; Resource - Ö.B., E.K.Ç., G.S.; Materials - Ö.B., E.K.Ç., G.S., E.Ç.T., C.S., M.D., A.Ö.; M.H.K.; Data Collection and/or Processing - Ö.B., E.K.Ç., G.S., E.Ç.T.; Analysis and/or Interpretation - Ö.B., E.K.Ç., G.S.; Literature Search - Ö.B., E.K.Ç., G.S., E.Ç.T.; Writing - Ö.B., E.K.Ç., G.S.; Critical Reviews - E.Ç.T., C.S., M.D., A.Ö., M.H.K.

Acknowledgements: The authors thank Sevilay Karahan, PhD (Department of Biostatistics, Hacettepe University School of Medicine, Ankara, Turkey) for helping to the statistical analysis.

Conflict of Interest: No conflict of interest was declared by the authors.

Financial Disclosure: The authors declared that this study has received no financial support.

References

1. Clayman MA, Clayman SM, Seagle MB. A review of the surgical and medical treatment of Frey syndrome. *Ann Plast Surg* 2006; 57: 581-4. [\[CrossRef\]](#)
2. Luers JC, Guntinas-Lichius O, Klusmann JP, Küsgen C, Beutner D, Grosheva M. The incidence of Warthin tumours and pleomorphic adenomas in the parotid gland over a 25-year period. *Clin Otolaryngol* 2016; 41: 793-7. [\[CrossRef\]](#)
3. Sood S, Quraishi MS, Bradley PJ. Frey's syndrome and parotid surgery. *Clin Otolaryngol Allied Sci* 1998; 23: 291-301. [\[CrossRef\]](#)
4. de Bree R, van der Waal I, Leemans CR. Management of Frey syndrome. *Head Neck* 2007; 29: 773-8. [\[CrossRef\]](#)
5. Marchese-Ragona R, De Filippis C, Marioni G, Staffieri A. Treatment of complications of parotid gland surgery. *Acta Otorhinolaryngol Ital* 2005; 25: 174-8.
6. Lin CC, Tsai MH, Huang CC, Hua CH, Tseng HC, Huang ST. Parotid tumors: a 10-year experience. *Am J Otolaryngol* 2008; 29: 94-100. [\[CrossRef\]](#)
7. Tuncel A, Karaman M, Sheidaei S, Tatlıpınar A, Esen E. A comparison of incidence of Frey's syndrome diagnosed based on clinical signs and Minor's test after parotid surgery. *Kulak Burun Bogaz İhtis Derg* 2012; 22: 200-6. [\[CrossRef\]](#)
8. Takahama Junior A, Almeida OP, Kowalski LP. Parotid neoplasms: analysis of 600 patients attended at a single institution. *Braz J Otorhinolaryngol* 2009; 75: 497-501. [\[CrossRef\]](#)
9. Rustemeyer J, Eufinger H, Bremerich A. The incidence of Frey's syndrome. *J Craniomaxillofac Surg* 2008; 36: 34-7. [\[CrossRef\]](#)
10. Nitzan D, Kronenberg J, Horowitz Z, Wolf M, Bedrin L, Chaushu G, et al. Quality of life following parotidectomy for malignant and benign disease. *Plast Reconstr Surg* 2004; 114: 1060-7. [\[CrossRef\]](#)
11. Perzik SL. End results in parotid tumors. *Calif Med* 1957; 86: 223-8.
12. Redaelli de Zinis LO, Piccioni M, Antonelli AR, Nicolai P. Management and prognostic factors of recurrent pleomorphic adenoma of the parotid gland: personal experience and review of the literature. *Eur Arch Otorhinolaryngol* 2008; 265: 447-52. [\[CrossRef\]](#)
13. Harada T, Inoue T, Harashina T, Hatoko M, Ueda K. Dermis-fat graft after parotidectomy to prevent Frey's syndrome and the concave deformity. *Ann Plast Surg* 1993; 31: 450-2. [\[CrossRef\]](#)
14. Dulguerov P, Quinodoz D, Cosendai G, Piletta P, Lehmann W. Frey syndrome treatment with botulinum toxin. *Otolaryngol Head Neck Surg* 2000; 122: 821-7. [\[CrossRef\]](#)
15. Pomprasit M, Chintrakarn C. Treatment of Frey's syndrome with botulinum toxin. *J Med Assoc Thai* 2007; 90: 2397-402.
16. Yoo YM, Lee JS, Park MC, Kim C, Seo SJ, Lee IJ. Dermofat graft after superficial parotidectomy via a modified face-lift incision to prevent Frey syndrome and depressed deformity. *J Craniofac Surg* 2011; 22: 1021-3. [\[CrossRef\]](#)
17. Roark DT, Sessions RB, Alford BR. Frey's syndrome-a technical remedy. *Ann Otol Rhinol Laryngol* 1975; 84: 734-9. [\[CrossRef\]](#)
18. Solish N, Bertucci V, Dansereau A, Hong HC, Lynde C, Lupin M, et al. Canadian Hyperhidrosis Advisory Committee. A comprehensive approach to the recognition, diagnosis, and severity-based treatment of focal hyperhidrosis: recommendations of the Canadian Hyperhidrosis Advisory Committee. *Dermatol Surg* 2007; 33: 908-23. [\[CrossRef\]](#)
19. Barberá R, Castillo F, D'Oleo C, Benítez S, Cobeta I. Superficial musculoaponeurotic system flap in partial parotidectomy and clinical and subclinical Frey's syndrome. *Cosmesis and quality of life. Head Neck* 2014; 36: 130-6. [\[CrossRef\]](#)
20. Amin A, Mostafa A, Rifaat M, Nabawi A, Shallan M, Rabie A, et al. Parotidectomy for benign parotid tumors: an aesthetic approach. *J Egypt Natl Canc Inst* 2011; 23: 67-72. [\[CrossRef\]](#)
21. Durgut O, Basut O, Demir UL, Ozmen OA, Kasapoglu F, Coskun H. Association between skin flap thickness and Frey's syndrome in parotid surgery. *Head Neck* 2013; 35: 1781-6. [\[CrossRef\]](#)
22. Santos RC, Chagas JF, Bezerra TF, Baptistella JE, Pagani MA, Melo AR. Frey syndrome prevalence after partial parotidectomy. *Braz J Otorhinolaryngol* 2006; 72: 112-5. [\[CrossRef\]](#)
23. Moltrecht M, Michel O. The woman behind Frey's syndrome: the tragic life of Lucia Frey. *Laryngoscope* 2004; 114: 2205-9. [\[CrossRef\]](#)
24. Guntinas-Lichius O, Gabriel B, Klusmann JP. Risk of facial palsy and severe Frey's syndrome after conservative parotidectomy for benign disease: analysis of 610 operations. *Acta Otolaryngol* 2006; 126: 1104-9. [\[CrossRef\]](#)
25. Casler JD, Conley J. Sternocleidomastoid muscle transfer and superficial musculoaponeurotic system plication in the prevention of Frey's syndrome. *Laryngoscope* 1991; 101: 95-100.
26. Curry JM, King N, Reiter D, Fisher K, Heffelfinger RN, Pribitkin EA. Meta-analysis of surgical techniques for preventing parotidectomy sequelae. *Arch Facial Plast Surg* 2009; 11: 327-31. [\[CrossRef\]](#)
27. Bonanno PC, Casson PR. Frey's syndrome: a preventable phenomenon. *Plast Reconstr Surg* 1992; 89: 452-6. [\[CrossRef\]](#)
28. Yu LT, Hamilton R. Frey's syndrome: prevention with conservative parotidectomy and superficial musculoaponeurotic system preservation. *Ann Plast Surg* 1992; 2: 217-22. [\[CrossRef\]](#)
29. Demirci U, Basut O, Noyan B, Demir UL, Afsin Ozmen O, Kasapoglu F, et al. The efficiency of sternocleidomastoid muscle flap on Frey's syndrome via a novel test: galvanic skin response. *Indian J Otolaryngol Head Neck Surg* 2014; 66: 291-8. [\[CrossRef\]](#)

30. Taylor SM, Yoo J, Matthews TW, Lampe HB, Trites JR. Frey's syndrome and parotidectomy flaps: A retrospective cohort study. *Otolaryngol Head Neck Surg* 2000; 122: 201-3. [\[CrossRef\]](#)
31. Kornblut AD, Westphal P, Miehke A. The effectiveness of a sternomastoid muscle flap in preventing post-parotidectomy occurrence of the Frey syndrome. *Acta Otolaryngol* 1974; 77: 368-73. [\[CrossRef\]](#)
32. Kierner AC, Zelenka I, Gstoettner W. The sternocleidomastoid flap--its indications and limitations. *Laryngoscope* 2001; 111: 2201-4. [\[CrossRef\]](#)
33. Allison GR, Rappaport I. Prevention of Frey's syndrome with superficial musculoaponeurotic system interposition. *Am J Surg* 1993; 166: 407-10. [\[CrossRef\]](#)
34. Dulguerov N, Makni A, Dulguerov P. The superficial musculoaponeurotic system flap in the prevention of Frey syndrome: A meta-analysis. *Laryngoscope* 2016; 126: 1581-4. [\[CrossRef\]](#)
35. Zhao HW, Li LJ, Han B, Liu H, Pan J. Preventing post-surgical complications by modification of parotidectomy. *Int J Oral Maxillofac Surg* 2008; 37: 345-9. [\[CrossRef\]](#)